

SURGICAL OPERATIONS


PART I.

THE LIGATURE OF ARTERIES

M19493

H x

19/m



22101625602

Handwritten note:
I received better copy
from my

SURGICAL OPERATIONS

PART I.

THE LIGATURE OF ARTERIES

Ballantyne Press

BALLANTYNE, HANSON AND CO., EDINBURGH
CHANDOS STREET, LONDON

SURGICAL OPERATIONS

PART I.

THE LIGATURE OF ARTERIES

*A SHORT DESCRIPTION OF THE SURGICAL ANATOMY AND
MODES OF TYING THE PRINCIPAL VESSELS*

BY

SIR WILLIAM MAC CORMAC

SURGEON, AND LECTURER ON SURGERY,
ST. THOMAS'S HOSPITAL



LONDON

SMITH, ELDER & CO., 15 WATERLOO PLACE

1885^h

13342

01886

M19493

WELLCOME INSTITUTE LIBRARY	
Coll.	welMOmec
Call	
No.	W0500
	1885-
	M13s

PREFACE.

MY purpose in publishing this account of the Ligature of Arteries is to give a brief, but I hope an accurate, statement of the manner in which the operations may be performed, and in each case of illustrating by diagrams the more important anatomical relations of the parts. For many of these I am indebted to the artistic skill of my friend and colleague, Mr. William Anderson. The descriptive matter was prepared, in the first instance, for members of the class attending my lectures. I desire to give only what is absolutely essential, and leave the student to gain afterwards, by more extended observation, reading, as well as practice on the dead subject, a greater knowledge of details.

WILLIAM MACCORMAC.

13 HARLEY STREET, *June* 1885.

CONTENTS.



LIGATURE OF ARTERIES.

Historical Introduction.—Position in which to apply ligature—Anel's method—Hunter's method—Brasdor's method—Deschamps' method—Wardrop's method—Antyllus' method Pp. 1-6

Indications to Ligature.—Wounds—Immediate ligature—Hunterian ligature—Aneurism—As a preliminary to other operations—With a view to starving morbid growths—Elephantiasis—Epilepsy—Contra-indications to ligature—Recent traumatic aneurisms—General arterial and heart disease—Multiple aneurism Pp. 6-10

Operation.—Position of patient—Instruments—Exposure of vessel—Application of ligature—Material—Double ligature—Closure of wound—Drainage Pp. 10-22

Action of Ligature upon Vessel.—Effect upon vascular coats—Temporary clot—Permanent clot—Organization of thrombus—Catgut or silk ligature—Temporary deligation—Presse-artère—Changes in an aneurismal sac after ligature of the artery—Collateral circulation—After-treatment—Causes of failure after ligature—Complications and causes of death after ligature—Gangrene—Secondary hæmorrhage Pp. 22-37

LIGATURE OF THE ARTERIES OF THE UPPER EXTREMITIES, NECK, FACE AND HAND.

Arteries of the Hand.—Digital arteries—Superficial palmar arch—Deep palmar arch—Radial—Ulnar—Brachial—Axillary—Subclavian—Vertebral—Inferior thyroid—Internal mammary—Innominate—Common

carotid—External carotid—Internal carotid—Superior thyroid—Lingual
 —Posterior auricular—Facial—Occipital—Temporal, middle menin-
 geal Pp. 38-97

LIGATURE OF ARTERIES OF LOWER EXTREMITIES AND PELVIS.

Plantar Arteries.—Dorsalis pedis—Anterior tibial—Posterior tibial—Peroneal
 —Popliteal—Superficial femoral—Common femoral—External iliac—
 Internal iliac — Gluteal — Sciatic — Internal pudic — Common iliac—
 Abdominal aorta Pp. 97-134

LIST OF ILLUSTRATIONS.



FIG.	PAGE
1. Diagram illustrating Anel's method of ligature	2
2. Diagram illustrating Hunter's method of ligature	2
3. Diagram illustrating Brasdor's method of ligature	4
4. Diagram illustrating Wardrop's method of ligature	4
5. Diagram illustrating Wardrop's method of ligature	4
6. Operating scalpel	10
7. Dissecting forceps	11
8. Toothed dissecting forceps	11
9. Director	11
10. Clamp pressure forceps (<i>pince hæmostatique</i>)	11
11. Wound retractor	12
12. Aneurism needles	12
13. Position of knife in commencing and terminating incisions	13
14. Position of knife in division of the tissues covering the artery	13
15. Position of knife in firmer incision	14
16. Incision of tissues on a director	14
17. Division of deeper layers of tissue in a wound	15
18. Division of tissue between two pairs of forceps	15
19. Opening of arterial sheath	16
20. Division of tissue between two pairs of forceps	17
21. Passage of aneurism needle	18
22. Knotting of ligature around artery	19
23. Reef knot	20
24. Double hitch knot	20
25. Granny	20
26. Drainage tube prepared for insertion	21
27. Sizes of drainage tubes	22
28. Forceps for introducing drainage tubes	23
29. Interrupted sutures	23
30. Probe for introduction of drainage tubes	23
31. Manner of introducing tube	23
32. Action of ligature on artery (Ext.)	23
33. Effect of ligature on internal and middle coats of artery	24

FIG.		PAGE
34.	Separation of the ligature	25
35.	Temporary clot, and collateral circulation after ligature	25
36.	Temporary clot, and collateral circulation after ligature, near a lateral branch	26
37.	Transverse section of femoral artery of dog eight days after ligature	27
38.	Transverse section of carotid artery of dog fifteen days after ligature	28
39.	Section of femoral aneurism cured by application of Esmarch's bandage, followed by digital compression	31
40.	Collateral circulation after ligature of right common femoral artery .	33
41.	Collateral circulation established after cure of popliteal aneurism .	33
42.	Ligature of brachial artery, one collateral branch	34
42.*	Collateral circulation after ligature of right brachial artery	34
43.	Position and mode of formation of palmar arches, and distribution of digital arteries	39
44.	Incision for finding superficial palmar arch	40
45.	Surgical anatomy of radial artery at wrist	43
46.	Position of incisions for ligature of arteries of arm and forearm .	44
47.	Transverse section through middle of right forearm	46
48.	Transverse section through middle of right arm	48
49.	Surgical anatomy of arteries of forearm	49
50.	Surgical anatomy of brachial artery	50
51.	Transverse section through middle of right arm	51
52.	Anastomosing branches of axillary and brachial arteries	53
53.	Surgical anatomy of axillary artery	54
54.	Position of incisions for ligature of axillary and brachial arteries .	56
55.	Diagram of innominate artery and right subclavian artery and its branches	58
56.	Diagram of left subclavian artery and its branches	59
57.	Anatomy of supra-clavicular fossa	60
58.	Position of incisions for ligature of temporal, lingual, facial, subclavian, axillary, and internal mammary arteries	62
59.	Surgical anatomy of the neck	63
60.	Anastomoses of subclavian and carotid arteries	67
61.	Transverse section of the neck at level of seventh cervical vertebra .	68
62.	Right subclavian artery and its branches	70
63.	Relations of inferior thyroid artery, carotid artery, recurrent laryngeal nerve and thyroid gland	71
64.	Diagram of innominate artery, right subclavian artery and branches .	74
65.	Surgical anatomy of the neck	77
66.	Surgical anatomy of the neck	78
67.	Section shewing relation of carotid artery to surrounding parts, at level of sixth cervical vertebra	80
68.	Diagram of carotid sheath	80

FIG.		PAGE
69.	Diagram of left common, external, and internal carotid arteries.	84
70.	External and internal carotid arteries, with principal branches of the former	86
71.	Principal branches of external carotid artery	89
72.	Distribution of arteries of face and head	92
73.	Position of incisions for ligature of temporal, lingual, facial, carotid, subclavian, axillary, and internal mammary arteries	94
74.	Relations of middle meningeal artery to surface of skull. Position of trephine opening for exposure of anterior branch	96
75.	Median transverse section of foot	98
76.	Transverse section of right ankle through malleoli	99
77.	Vertical section through ankle-joint	100
78.	Surgical anatomy of anterior tibial and dorsalis pedis arteries	101
79.	Transverse section through the middle of right leg	102
80.	Position of incisions for ligature of anterior tibial and dorsalis pedis arteries	103
81.	Surgical anatomy of posterior tibial and peroneal arteries	105
82.	Collateral circulation in the leg and at ankle	107
83.	Surgical anatomy of popliteal artery	110
84.	Collateral circulation established after ligature of both femoral arteries (anterior view)	114
85.	Collateral circulation established after ligature of both femoral arteries (posterior view)	115
86.	Transverse section of the right thigh at apex of Scarpa's triangle	116
87.	Surgical anatomy of the iliac and femoral arteries	117
88.	Position of incisions for common femoral, superficial femoral, femoral in Hunter's canal, and posterior tibial arteries	118
89.	Anastomoses of iliac and femoral arteries	120
90.	Surgical anatomy of gluteal, internal, pudic, and sciatic arteries	126
91.	Position of incisions for ligature of gluteal, sciatic, and internal pudic arteries	127
92.	Position of incisions for ligature of common and external iliac arteries	130
93.	Surgical anatomy of abdominal aorta, iliac, and femoral arteries	132

SURGICAL OPERATIONS.

LIGATURE OF THE ARTERIES.

DIEFFENBACH is reported to have said that "what printing is for knowledge and gunpowder for war, the discovery of the ligature of arteries is for surgery." To Ambrose Paré has sometimes been attributed this great merit, but the ligature of vessels was employed long before his time; indeed, Paré himself mentions Galen as recommending it. In the early period, however, a large portion of the surrounding tissues was included in the ligature, and often, of course, the adjacent nerves and veins. This is the so-called mediate ligature, a bad method in all respects, but one which held its ground till a comparatively recent period, when it was seen that it increased the frequency of secondary hæmorrhage, and produced great suffering from the inclusion of nerves. Deschamps, in 1797, first formulated the complete isolation of the artery as the proper practice. The artery, from this time forward, was carefully separated from the surrounding tissues, and the immediate form of ligature soon became universal. The older methods of treating aneurism were very severe and very unsuccessful, direct pressure on the sac, tight bandaging of the limb, laying open the sac of the tumour and ligaturing the vessels connected with it, trying to arrest the flow of blood with the actual cautery, strong styptics, or amputation, were common expedients. About a hundred years ago, Hunter introduced his method of ligature, and thus revolutionized the manner of treating aneurism. The method of treatment by compression, which is often successfully substituted for ligature, was introduced by the Dublin School of Surgery forty years

ago, and in the hands of Irish surgeons more especially it has to a great extent put the ligature aside.

The tying of arteries, however, is likely to continue to be necessary in very many cases.

The ligature of an artery in its continuity must be distinguished from the ligature of the cut extremity of a vessel in a wound, as, for instance, one made for the amputation of a limb or removal of a tumour. In the latter the bleeding points are already plainly exposed upon the surface of the wound. They may be seized with an appropriate forceps,

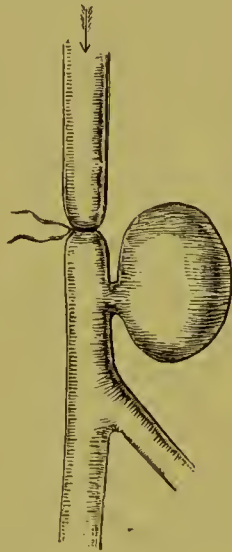


FIG. 1.—Anel's method.

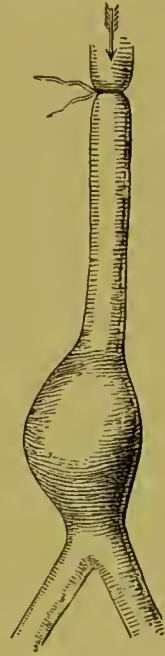

FIG. 2.—Hunter's method.

and the open extremities secured either by the ligature, by torsion, or by acupressure. When, however, the continuity of the vessel is unbroken, and the place where the ligature has to be applied is covered by a greater or lesser thickness of soft parts, the vessel at the point of ligature must be exposed by careful dissection. In some cases this is easily done, while in others it may be very difficult. A knowledge of the anatomical relations of the artery and direction of its course with respect to the surface of the body becomes essential.

POSITION IN WHICH TO APPLY THE LIGATURE.—An artery affected by aneurismal swelling may be ligatured between the diseased point and the

heart, either quite close to the aneurism, or at a distance from it. The former, the older method, often termed Anel's (Fig. 1), is open to the serious drawback that the vessel will commonly be found diseased at the place where the ligature must be applied. Its obliteration, therefore, is often imperfectly accomplished, and secondary hæmorrhage will be very liable to follow. These objections do not apply to aneurisms of traumatic origin, nor to wounds of vessels; to these, this method may often be successfully applied.

Anel's first operation was performed in 1710, for traumatic aneurism at the bend of the elbow. He exposed and tied the brachial artery as near the tumour as possible. The objections to the general application of Anel's method are that there is no current of blood through the aneurism except perhaps a weak reflux wave, a soft clot forms in place of a firm laminated one, and hence the obliteration of the sac is less certain and perfect. The disturbance of the sac and its connections during the operation, and the risk of wounding it, must needs be considerable; the vessel probably lies at great depth, may be very difficult to reach, the more so as we have often no exact guide to its position. The tumour may suppurate; gangrene is more likely to occur from the incomplete establishment of the collateral circulation; and lastly, the vessel will in all probability be diseased at the place of ligature.

Hunter recognised these causes of failure, and has the merit of obviating them in cases of so-called idiopathic aneurism, by his proposal to ligature the artery at a sufficient distance from the disease (Fig. 2). Hunter's discovery was threefold: first, it showed that the ligature of the main vessel does not necessarily involve gangrene of the limb below; secondly, that it is undesirable to employ any local treatment to the aneurism itself; and thirdly, that for its obliteration by a coagulum it is only needful to abate the force of the blood current, and not entirely to arrest it. Hunter therefore proposed to ligature the artery at a distance above the sac, that is, nearer to the heart. His method of operation has been subsequently modified in details. He used to tie the femoral artery in the so-called "Hunter's canal," and was not careful to avoid including the vein. Yet the principles he laid down have been acted upon ever since, and have revolutionized the treatment of aneurism. Perhaps the most important

point involved in his practice is that it has proved it to be unnecessary to shut off absolutely all the blood current through the aneurismal sac. It is only needful so to diminish its volume and speed as to allow the blood to coagulate in layers within the sac, and thus procure the final obliteration of its cavity. The same principle is applied in the treatment of aneurism by compression, except where a rapid cure is attempted by complete compression. Sir Everard Home first pointed out that a partial entrance of blood into the sac soon takes place when the artery is tied at a distance. But this is for some time completely prevented when the artery is tied

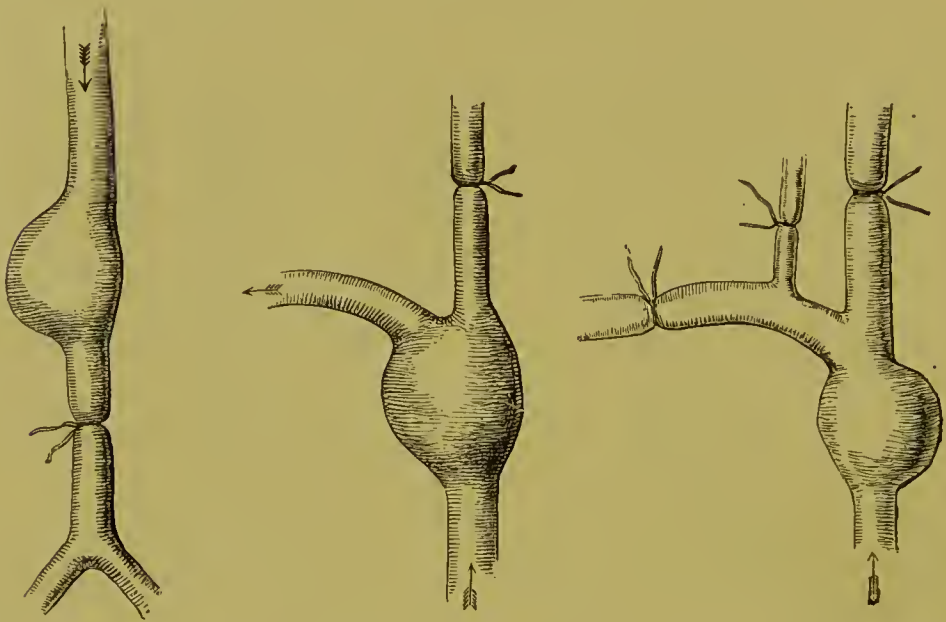


FIG. 3.—Brasdor's method. FIG. 4.—Wardrop's method. FIG. 5.—Wardrop's method.

close to the sac. When the vessel is ligatured at a distance, the collateral circulation very speedily becomes re-established, and there is less liability to gangrene of the limb or suppuration in the sac.

The distal ligature, or the occlusion of the vessel beyond the aneurism (Fig. 3), was proposed by Brasdor for the treatment of aneurisms in which other methods are not available; the object aimed at being to diminish the entrance of blood into the sac and direct it through other channels by cutting off the main emergent artery. In this way a considerable portion of the flow of blood to the aneurism is diverted into adjacent arteries, the

sac contracts, the pulsation becomes fainter, and the coagulation of its contents is favoured. An aneurism, for instance, near the commencement of the common carotid artery should be dealt with by ligature of the trunk of the vessel beyond the aneurism, rather than by the almost inevitably fatal ligature of the innominate artery. This principle appears to have been first applied by Deschamps in 1799 in a case of femoral aneurism; it rests on a sound pathological basis, the process of cure corresponding exactly to that observed in cases where spontaneous recovery has resulted from closure of the efferent vessel by an embolus, or shifting of the clot.

Wardrop in 1825 adopted and extended the proposition of Brasdor. He applied the distal ligature even to cases where, unlike the example cited of the carotid artery only a comparatively small proportion of the blood current flowing out of the aneurism can be arrested. For instance, in the case of an aneurism at the root of the neck, involving the innominate artery, the carotid artery (Fig. 4), or the carotid together with the subclavian in its third stage might be tied either simultaneously or in succession (Fig. 5).

This method of treatment is very uncertain, and the beneficial results are usually only temporary. The tension is often greatly increased. The sac may even burst, or suppuration, sloughing, and hæmorrhage take place. Some of the cases, however, in which it has been adopted prove that the increase of the aneurism may be arrested for a longer or shorter interval, and the disease in a few instances cured. The more completely the blood current is cut off on the distal side, the more likely is success to follow. If a considerable branch intervene between the ligature and the sac, the curative influence of the operation will be by so much diminished, unless the branch can also be secured (Fig. 5).

Lastly, the method known as that of Antyllus, a renowned Greco-Roman surgeon who flourished 350 A.D., has been adopted in a few instances of aneurism, chiefly of traumatic origin. It is a survival of the older methods of direct treatment by pressure and otherwise, applied to the aneurismal tumour itself. According to this plan the aneurismal sac is exposed, laid open from end to end, the clots rapidly turned out, and the points of entrance and exit of the artery sought for. These are then to be secured by two ligatures, and the large cavity exposed suitably dressed and allowed

to heal by granulation. This operation is tedious, dangerous, and applicable only to exceptional cases. It involves a considerable risk of failure at the time, and of surgical casualty during the after-treatment. The bloodless method of operating, by means of Esmarch's elastic bandage, much facilitates the steps of this operation. The method of Antyllus is often very difficult, especially when the artery enters the deeper portion of the aneurismal sac. The operation entails an incision of great length, involves much hæmorrhage, and there is an enormous cavity to be afterwards filled up by granulation. In some cases it was impossible to secure the bleeding vessels by ligature, and the actual cautery or styptic applications had to be resorted to, generally with but little effect. For popliteal aneurism, the operation of Antyllus used formerly to be the only alternative treatment to amputation, and very generally it proved fatal. John Bell and Syme adopted it in cases of axillary and gluteal aneurism. It is suitable for traumatic aneurism in the axilla, small traumatic aneurisms at the bend of the elbow and elsewhere, for cases of burst sac, or for a wound implicating the aneurism. In rare instances it may be indicated in spontaneous aneurism, where proximal ligature has failed as a result of too free collateral circulation, or the sac is supplied by a number of afferent vessels, as may be the case in femoral aneurism, in the neighbourhood of the origin of the profunda.

In performing the operation Syme incised the sac at first only just enough to enable him to introduce either one or two fingers. He searched till he found the place where pressure would control the hæmorrhage, the opening meanwhile being plugged by the fingers. Then he laid open the sac freely, cleared away the clots, secured the vessel with forceps, and tied it above and below. If the artery was not plainly exposed in the cavity of the sac, the tissues surrounding it were separated sufficiently to apply the ligature, the hæmorrhage meanwhile being controlled by pressure with the finger.

Gangrene is a common sequence of this plan of treatment in cases of spontaneous aneurism, and secondary hæmorrhage may also frequently result because of the diseased condition of the vessel.

INDICATIONS TO LIGATURE.—There are two chief reasons which may necessitate the formal search for an artery, and its complete ex-

posure in the wound, with a view to the application of a ligature. The first is a wound of the vessel. Wounds of the larger arteries should invariably be ligatured, treatment by compression, applied either locally or at a distance, being inapplicable. These injuries may be caused either by puncture or cut, by laceration or contusion such as is produced by gunshot, or rupture of the vessel by indirect violence, which sometimes happens during the reduction of old-standing dislocations or the forcible straightening of flexed and partially ankylosed joints. In cases of traumatic origin, the same practice, as a rule, applies. An attempt should be made to expose the vessel where it has been wounded, and apply a double ligature—one above the seat of injury, and the other below it. It is only when this attempt fails from inability to discover the bleeding points, or where renewed hæmorrhage occurs after the application of the ligature, and further local search fails, that the vessel should be tied at a distance.

In a large accessible wound, hæmorrhage should be dealt with by local ligature of all bleeding points, but it is a different matter in the long narrow channel produced by a rifle bullet. To reach the seat of hæmorrhage in the deeper portions of such a wound very large incisions may have to be made. Possibly a comminuted fracture may be present. In gunshot injuries associated with fracture and hæmorrhage, the long devious gunshot track may offer insuperable difficulties in accomplishing what is theoretically the best practice, to wit, the application of a double ligature to the vessel at the injured point; but probably it will be best to make the attempt, at least in all cases of primary bleeding. When the hæmorrhage is secondary and the wound granulating or suppurating, the local search for the bleeding points is very hopeless, and too frequently, when constrained to apply a ligature on the main vessel after the Hunterian method, we find it has but little practical control over the hæmorrhage. In cases of traumatic origin generally the hæmorrhage is not likely to be arrested by the Hunterian method. Opinion is divided as to the better course to adopt, but most authorities are in favour of making an attempt to secure the bleeding point in the wound both in cases of secondary as well as of primary hæmorrhage. In some special cases, such as repeated bleeding from wounds of the palmar arches, the ligature of

the main trunk at a distance may become necessary. In traumatic aneurism of small vessels the methods of Anel and Antyllus are those most generally applicable, if compression fail. As a rule, recent traumatic aneurisms following injury to a healthy artery are to be treated like wounded arteries. The ligature at least may be safely applied close to the aneurism in these cases, as the vessel wall is healthy both above and below the sac. The tumour has sometimes been laid open according to the method of Antyllus, the clots rapidly turned out, and the vessel secured at the points of entrance and exit.

Amongst the indications which may necessitate the Hunterian ligature of an artery in its continuity is serious hæmorrhage from a deep wound, the source of which is uncertain, and cannot be dealt with locally, as, for instance, in cases of hæmorrhage, where the wound from its position cannot be laid freely open. The uncertainty of the source of the bleeding in such cases is, however, unfavourable to successful ligature at a distance, as one may tie an artery which has no relation to the bleeding.

Inflammatory or other changes at the point of injury, which prevent a ligature being securely applied, is another indication, as also cases where a number of branches having a common origin have been injured. A wound of an important branch close to its origin from the main trunk, and hæmorrhage taking place from ruptured arteries beneath the unbroken skin in connection with fractures or dislocations, and other kinds of violence, may also require ligature of the vessel at some distance above.

Aneurism dependent upon arterial disease is the second chief reason for ligaturing arteries. In this case, when treatment by compression fails, the artery is to be tied at a distance from the disease. Aneurism of this form increases in frequency as the vessels increase in size. Spontaneous aneurism of the arm and forearm is very rare, and below the knee it is also of very exceptional occurrence. When aneurism forms at the bend of the elbow it is almost invariably of traumatic origin, and axillary aneurism, as well as popliteal, is frequently dependent upon a similar cause. Aneurism of an artery in a position inaccessible to pressure, and not amenable to other forms of treatment—as, for instance, most carotid and iliac aneurisms—may properly be made the subject of operation by ligature. If the patient be irritable, intolerant of pressure and other methods, we

must probably ligature the artery leading to the aneurism, or if an aneurism burst, the ligature of the principal artery, if not amputation of the limb, will be required. The Hunterian operation in the case of the innominate artery and abdominal aorta is contra-indicated on the ground of its fatality. The distal ligature after the methods of Brasdor and Wardrop has proved very unsuccessful in its application to the arteries of the lower half of the body, but in cases of aneurism of the innominate and the first portions of the carotid or subclavian, or of the arch of the aorta, it has sometimes acted beneficially. Those cases of spontaneous aneurism which are of slow increase, not of great size, and of firm consistence, exhibiting, in fact, a tendency to cure by the deposition of layers of fibrine in their interior, are the most favourable for ligature. The state of the heart and arterial system should be examined, and, if possible, the condition of the portion of artery about to be ligatured. It may happen that an operation for ligature must be abandoned, as the artery when exposed has been found too much diseased.

An artery is occasionally tied in its continuity, as a preliminary to certain operations, for the purpose of controlling the hæmorrhage. Archigenes first suggested the ligature of the main artery before an amputation or other operation was performed. The femoral or external iliac artery has occasionally been ligatured before performing amputation at the hip-joint, and the subclavian artery previous to removal of the scapula, or disarticulation at the shoulder-joint. The carotid artery has been tied prior to the removal of tumours in the neck. Graefe in 1821, and Mott in 1822, tied the carotid before extirpating the jaw, as a preliminary.

Arterial ligature has been employed with a view to starving morbid growths, and thus arresting their progress. Lange, in 1817, proposed to ligature the superior thyroid artery for goitre, but the operation was first performed by Sir Thomas Blizard in 1819. The lingual artery has been frequently tied in cases of cancer of the tongue. Ligature of the femoral has been unsuccessfully tried in cases of elephantiasis of the leg. Again, the carotid and vertebral arteries have been tied in cases of epilepsy, but with very doubtful benefit.

CONTRA-INDICATIONS TO LIGATURE.—As a rule, a ligature should not be applied to an artery for aneurism which can be treated by either digital or instrumental compression, until a trial of pressure fail.

It is not applicable to recent traumatic aneurisms until a period of rest, combined with pressure both direct and indirect, have proved useless. It should be remembered that this form of aneurism is not unlikely in some cases to undergo spontaneous cure.

In general arterial disease, and especially heart disease, the method of ligature should not be adopted. Internal aneurism, or the presence of several aneurismal tumours, is a contra-indication. Aneurisms in two limbs, however—as, for instance, two popliteal aneurisms—have been treated in succession by proximal ligature with success (Figs. 84, 85).

POSITION OF THE PATIENT.—The patient must be placed in a good light, with the part of the body to be operated upon in the position most




FIG. 6.—Scalpel.

accessible for the operator. The region having been thoroughly explored and the relations of the adjacent parts determined, assistants should keep the patient steadily in the same position until the operation shall be completed.

If it be a limb which is to be operated on, it should be placed in a convenient attitude for the operator, generally in a flexed position, and firmly held by an assistant.

INSTRUMENTS.—A scalpel (Fig. 6), dissecting forceps (Fig. 7), toothed forceps (Fig. 8), director (Fig. 9), pressure forceps (Fig. 10), retractor (Fig. 11), aneurism needles (Fig. 12), aseptic silk thread or catgut of

a size in proportion to that of the vessel requiring ligature, are the chief appliances needed.



FIG. 7.—Dissecting forceps.




FIG. 8.—Toothed forceps.



FIG. 9.—Director.

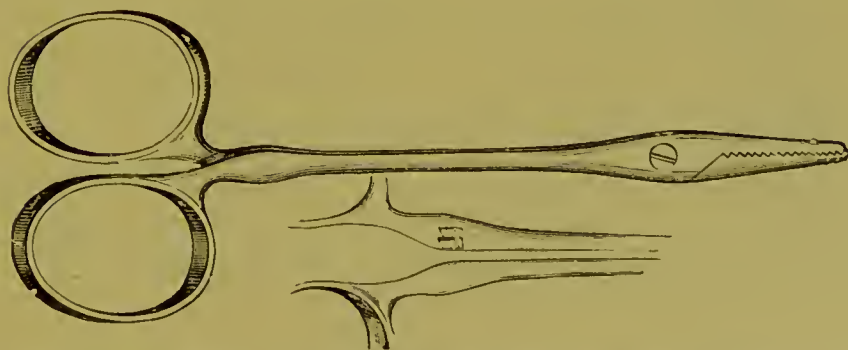

FIG. 10.—Clamp pressure-forceps to secure bleeding points in the wound, previous to tying the vessel.

EXPOSURE OF VESSEL.—A correct knowledge of anatomy is essential. Surgical landmarks indicating the relation of the vessel to the



FIG. 11.—A convenient form of retractor or holding aside the surfaces of the wound.

external surface should be carefully studied. The exact course of the vessel is, if practicable, to be traced on the body.

Note the presence of large superficial veins or abnormal arteries, and if possible avoid injuring them.

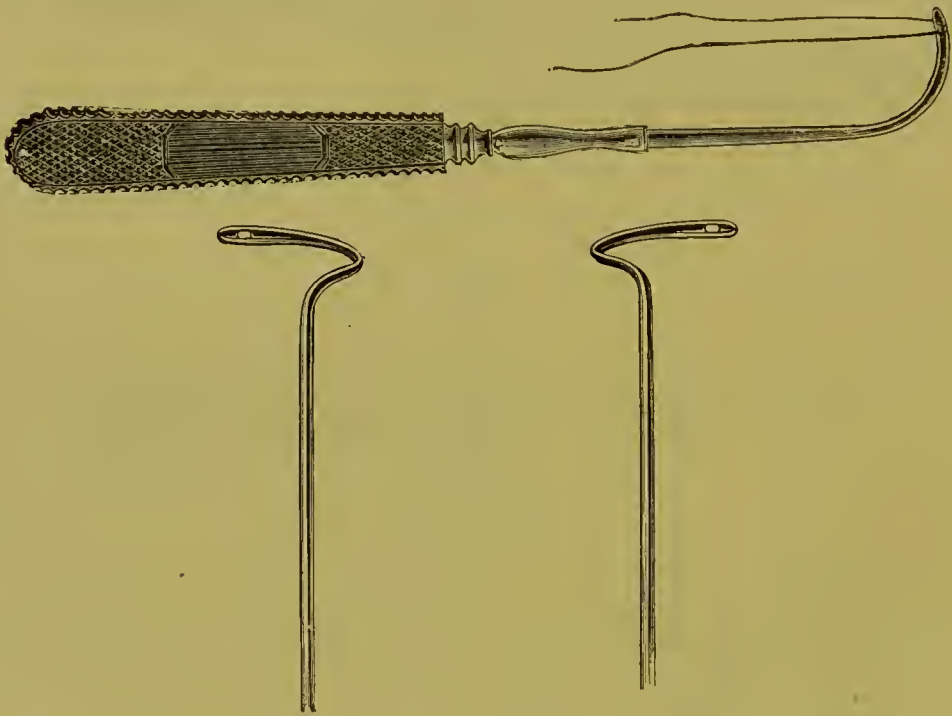


FIG. 12.—Different forms of aneurism needle. Saviard, towards the end of the seventeenth century, devised an aneurism needle very similar to that now in common use. From his all subsequent ones have been copied. Dupuytren introduced the doubly bent form. The end being at right angles to the handle, is therefore passed rather by a turn of the wrist than by a pushing movement.

Make a sufficiently long external incision precisely over the course and in the direction of the artery, in nearly all cases. It is better to err on the

side of making a free external incision. Too small a wound causes embarrassment in all the future stages of the operation.

Divide the skin in its whole thickness from end to end, steadying it with the fingers of the opposite hand to avoid displacement (Fig. 17).




FIG. 13.—Position in which to hold the knife when commencing and terminating the superficial incision.

Insert the point of the knife almost at right angles to the surface when beginning the incision (Fig. 13). Then slope it and complete the incision, the knife being again held nearly at right angles to avoid “tailing” of the wound, which would cause unnecessary pain afterwards.




FIG. 14.—Position of the hand and scalpel when dividing the layers of tissue covering an artery.

For light strokes, needed to divide the tissues covering an artery, it is usual to hold the knife somewhat as a pen is held (Fig. 14). When greater

force is required, as in most other operations, the instrument should be grasped like a dinner-knife (Fig. 15).

Divide the subcutaneous cellular tissue and fat throughout the whole extent of the superficial wound, laying bare the deep fascia or aponeurosis.

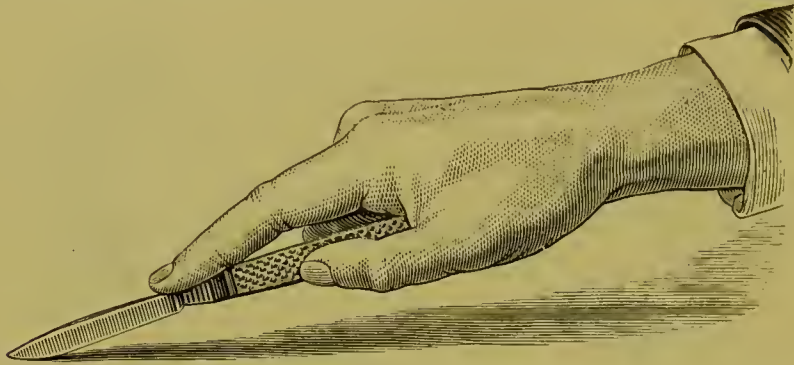


FIG. 15.—Manner of holding the knife when greater power is required.

Incise this to a corresponding extent, with or without the aid of a director. The aponeurosis is generally best divided on a director (Fig. 16).

Seek for the muscular interstice, which is usually indicated by a yellow

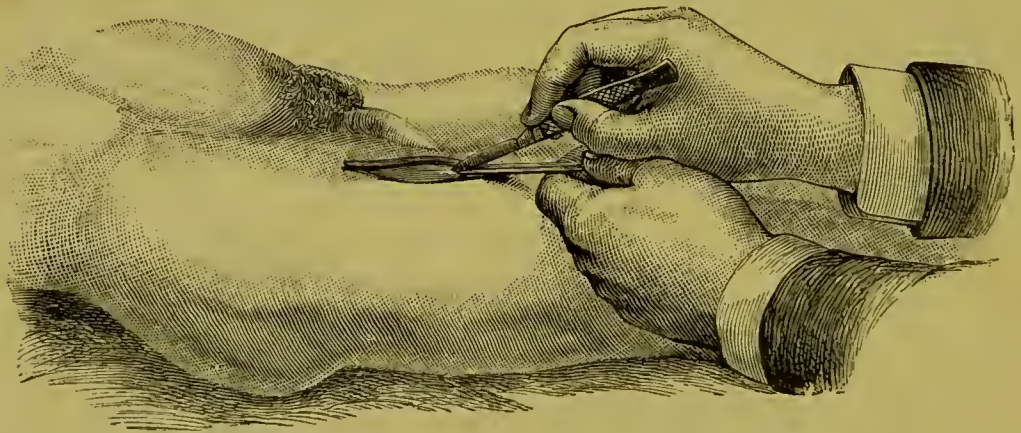


FIG. 16.—Manner of incising the tissues upon a director.

or sometimes a glistening white line, and sometimes by the presence of the perforating vessels. Division of the muscular fibres is not often required, the muscles are usually drawn aside. It is very desirable to steady the skin and superficial parts with the left hand, and to divide the sub-

cutaneous fat and deeper structures in the manner represented in Fig. 17. This will prevent the deeper part of the wound deviating in direction from the superficial incision.

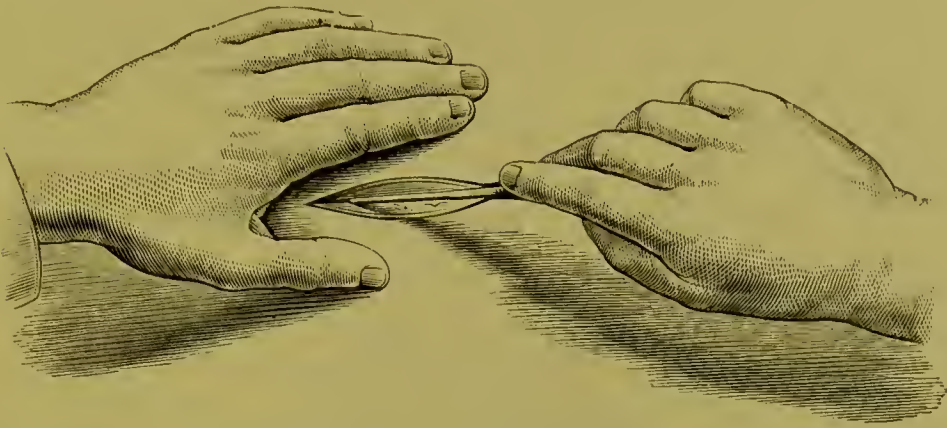


FIG. 17.—Method of dividing the deeper layers of tissue in the wound.

A ready and safe manner of dividing the deeper layers is shown in Figs. 18 and 20. The knife is used to divide the structures raised up between two forceps. A deep-lying fascia, or the arterial sheath itself,

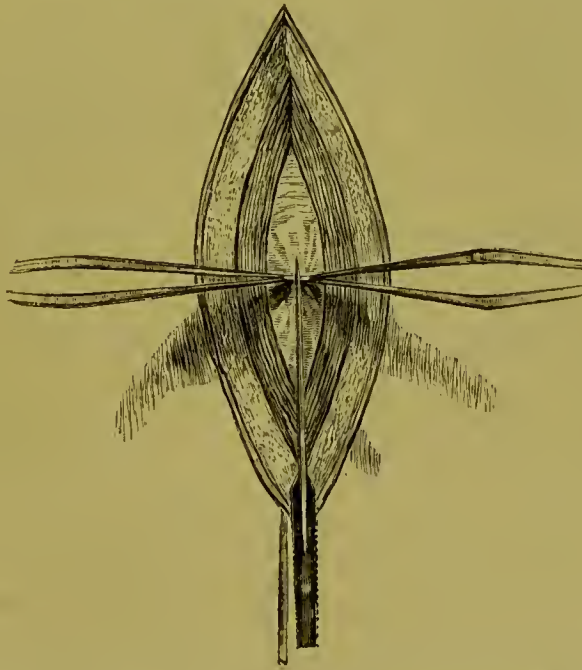


FIG. 18.—Manner of dividing the tissues when raised up between two pairs of forceps.

can be thus divided with great ease, and without incurring any risk of wounding other parts.

Tie all bleeding points as you proceed, or secure them with pressure forceps (Fig. 10). This is very necessary, because bleeding will obscure the bottom of the wound and prevent a distinct view of the tissues which are to be divided.

Then fully flex the limb, separate the relaxed muscles, and hold the parts aside by retractors (Fig. 11).

By a careful dissection expose sufficiently and quite distinctly the sheath

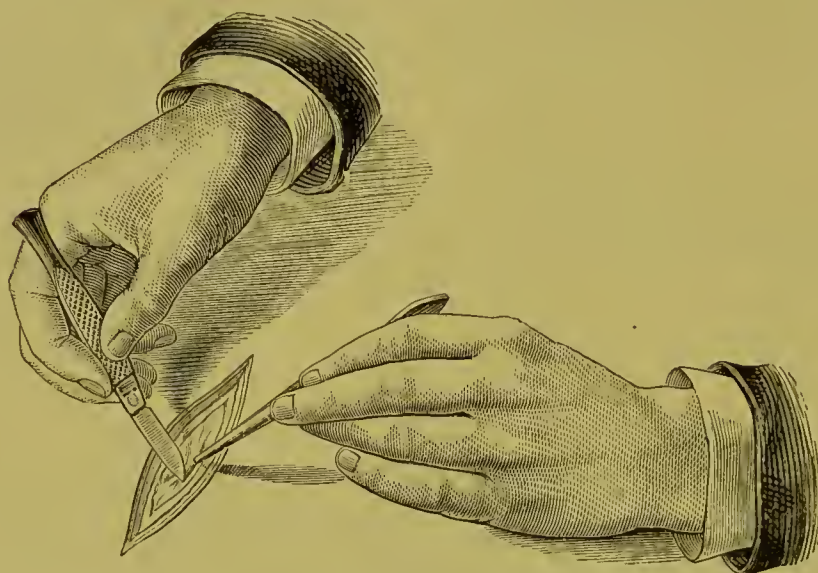


FIG. 19.—Position of the knife and forceps in the act of incising a layer of fascia, or the arterial sheath.

of the vessel, and then open the arterial sheath, to a limited extent, in the following manner.

Pinch up the sheath transversely to the long axis of the vessel with a forceps. Open it as you would a hernial sac, and only enough to allow the aneurism needle to pass easily, the flat surface of the knife being directed towards the artery (Fig. 19). In some cases it may be necessary after incision to tease it open with the end of a director, but this must be done very carefully, to avoid all needless injury to the vascular connection of the artery with its sheath. If the director be used, introduce it into the

opening in the sheath, and by a very gentle to-and-fro movement make a small channel on both sides of the vessel for the needle to pass more easily.

Always isolate a large artery at the point to be ligated as completely as possible, but only just sufficient to allow the aneurism needle to pass with ease. To include adjacent tissues renders the action of the ligature imperfect. The knot may become loose, and secondary hæmorrhage will be more likely to occur. Besides, there is a great risk of injuring neighbouring structures of importance.

The healing of the ligated artery can only take place favourably while it continues to receive a due supply of blood through its vasa

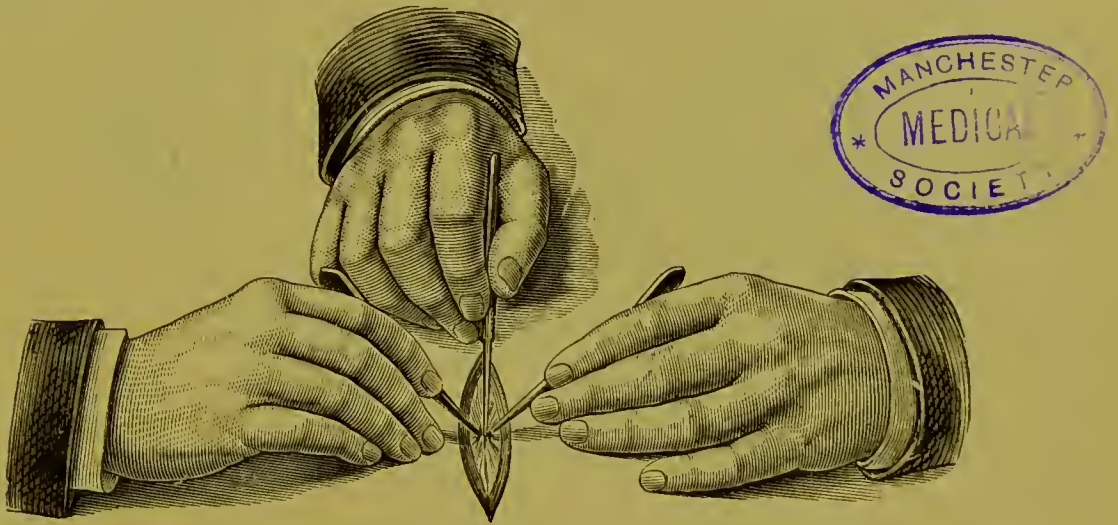


FIG. 20.—Manner of dividing the tissues between two pairs of forceps.

vasorum. Hence the importance of disturbing the connections of the vessel as little as possible, and applying the ligature as closely as may be to that part which lies undisturbed in the surrounding tissues.

The main nerves are generally superficial or external to the artery. Each large artery is accompanied by a yet larger vein.

The principal arteries go nearly straight to the place of distribution. They are to be found in the least exposed aspect of the limb, deeper than the corresponding veins, and protected by fascia.

The smaller arteries are usually accompanied by two veins united by cross branches. It is better when applying a ligature to exclude the veins in all cases. When they are small, however, and have connections

stretching across the vessel, their separation may be difficult, and it is not a matter of much moment if they be included in the ligature and tied along with the artery.

In the living subject, after exposure of the vessels, the veins are generally turgid, while the arterial pulsation may be faint or almost imperceptible. The artery assumes a flattened condition, both to the touch and sight, and slips under the finger. A nerve may be distinguished by its being round and tense. Always feel for the pulsation of the vessel in the wound, for though it may be feeble, it is the surest guide.

APPLICATION OF THE LIGATURE.—Carefully select and test beforehand the quality of the ligature thread, as its rupture during application may

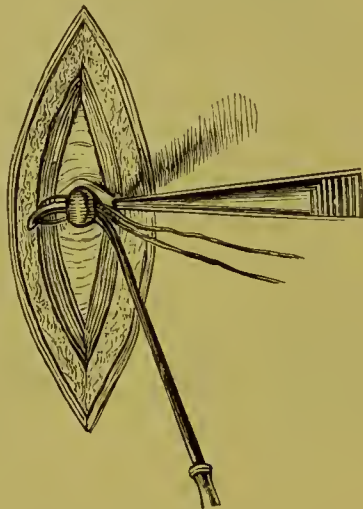


FIG. 21.—Manner of passing the aneurism needle around the artery. In the drawing the position of the forceps has not been changed.

inflict serious injury on the vessel. Various materials have been used ; for example, Japanese twist, a kind of silk thread, hemp cord, and certain animal tissues, such as prepared catgut, kangaroo and other tendons, strips of large nerves and bullock's aorta. Horsehair, silver, lead, and iron wire, with other substances have had a trial. Whatever be selected, the ligature should be round, smooth, of uniform moderate thickness, and the knot must be tightly drawn to ensure the complete division of the internal and middle coats. A return has recently been made in some instances, more especially in the case of large and not very healthy vessels, to the

practice of simply constricting the vessel. A broad tape-like ligature of animal substance is used, and the inner and middle coats are not divided.

When the vessel is thoroughly isolated and exposed, separate the margins of the wound with retractors. Pick up one edge of the divided sheath with the forceps. Insinuate the end of the needle gently around the vessel with a slight lateral to-and-fro motion, seizing the other margin of the opening in the sheath as the aneurism needle comes round, to facilitate its emergence (Fig. 21). The aneurism needle is often more easily passed unarmed. The eye can be readily threaded afterwards. If a portion of sheath catch on the end of the needle, it should be scratched




FIG. 22.—Manner of fastening the loop of ligature around the artery.

through with the finger-nail or knife. Avoid the use of any force. Carefully avoid all unnecessary disturbance of or dragging upon the artery, not only during the process of exposure, but in the act of applying the ligature.

Push the main vein aside with the finger, which will, at the same time, empty it of blood and place it in less danger of injury. Pass the needle with its convexity turned towards the vein, and towards the principal nerve also, if possible.

Before tying the knot assure yourself that the blood-current can be arrested by the ligature, and that nothing besides the vessel shall be included.

Tie strongly but steadily, always strictly at right angles to the long axis

of the vessel, and with force sufficient to divide the inner and middle coats with the first loop of the ligature. Immoderate force is never required. Press the forefinger of each hand well down in the wound, so as to prevent the artery being drawn forwards out of its sheath (Fig. 22).

The double hitch-knot (Fig. 24) is a good kind to employ, as the first loops will not slip. It avoids the objection of the possible failure to make a reef-knot (Fig. 23), thus entailing the disadvantages which the "granny" (Fig. 25) may occasion if it become loose. This latter kind of knot has certainly slipped on some occasions, and hæmorrhage or failure to obliterate the vessel has been the result. Whether for ligature of an

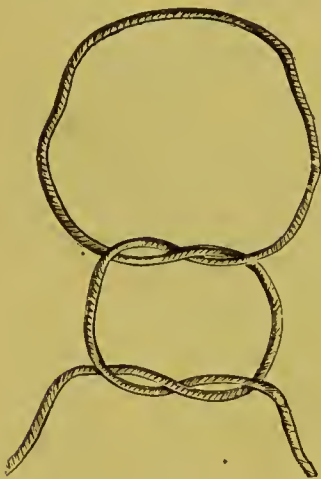


FIG. 23.—Reef-knot.

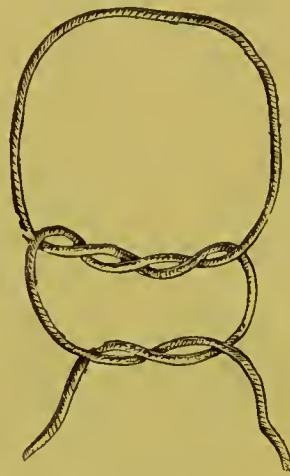


FIG. 24.—Double hitch or surgical knot.

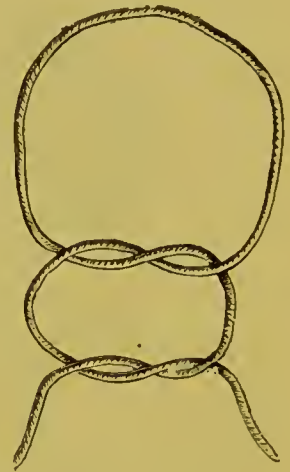


FIG. 25.—Granny.

artery or the suturing of a wound the double hitch is generally the best. It is not so suitable, however, if the ligature cord be very thick.

Formerly silk thread was generally employed as the best kind of ligature, and it should still continue to be used in a suppurating wound. One end was cut off close and the other left hanging out of the wound made to reach the artery, the separation usually taking place in ten days or a fortnight, according to the size of the vessel. When the loop came away it often contained a small portion of dead tissue consisting of the external cellular coat of the vessel (Fig. 34). The period of separation of the ligature was always one of much anxiety, as then it was that secondary bleeding was most likely to occur. We now prefer to use catgut, and in all cases to cut off both ends short, and close the external wound.

In some instances a double ligature is applied, the vessel divided between them, and the ends allowed to retract. This practice has been revived from time to time since Celsus advised it, although the Arabians and Greeks adopted it even before his day. John Bell and Abernethy reintroduced the practice in modern times, and were strongly in favour of it, as also was Sédillot. Secondary hæmorrhage was observed to be much less frequent after amputation than it was after application of a ligature for aneurism, and it was believed that by this method of applying a double ligature and dividing the vessel between, this tendency would be diminished. The artery is able to retract somewhat on each side after division, the tension is lessened, and its condition in consequence resembles that of a vessel tied on the face of a stump. The artery, too, under these circumstances,

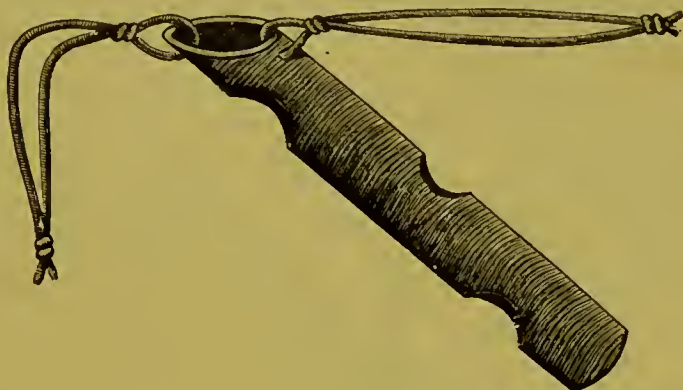


FIG. 26.—Drainage tube, prepared for insertion.

may be tied nearer to its undisturbed connections, a practice which it may be well to adopt in cases where an unhealthy wound already exists, or where the patient's general condition is such as to render primary union of the wound improbable.

The safety and greater facility of employing, as a rule, only a single ligature, is however amply demonstrated by experience, and the advantages of the other method are not so considerable as to lead to its general adoption. In cases where the artery lies deeply, where the external wound is comparatively small, and where surrounding structures are important and space limited—as, for instance, near to the iliac arteries, the innominate, or the subclavian artery—it may be quite impossible to isolate the vessel sufficiently to apply two ligatures and divide the artery between them.

It will also be more difficult to discover the end of the divided artery if secondary hæmorrhage ensue. The presence of a lateral branch may

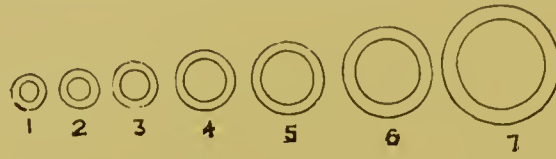

FIG. 27.—Seven different sizes of india-rubber drain tubing.

likewise occasion serious embarrassment, or render double ligature impracticable.

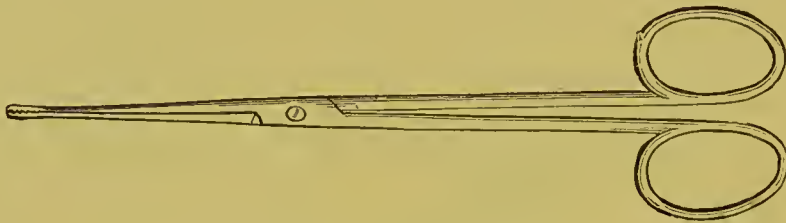


FIG. 28.—Forceps to introduce drainage tubes.

CLOSURE OF THE WOUND.—To complete the operation, the edges of the superficial wound must be accurately brought together with interrupted

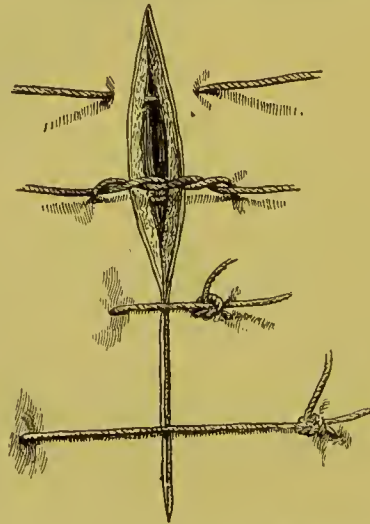


FIG. 29.—Interrupted sutures, superficial and deep.

sutures (Fig. 29), and a drainage tube or tubes of suitable size inserted. The drainage tube (Fig. 26) is usually made of india-rubber, with lateral openings. The size varies with the extent and depth of the wound (Fig. 27). A slender forceps, such as that shown in Fig. 28, may be used

to introduce the tube. The probe (Fig. 30) is a convenient instrument with which to pass a drainage tube to the bottom of the wound after it has been partially closed. One of the lateral openings near the extremity is hooked on the instrument, and the tube slightly stretched to prevent



FIG. 30.—Probe wherewith to introduce drainage tubes.

it slipping off (Fig. 31). It can then be passed with facility to the full depth of the wound, when, on relaxing the tube, the probe may be withdrawn, leaving the former in the desired position.



FIG. 31.—Manner in which the drainage tube may be passed into the wound.

ACTION OF THE LIGATURE UPON THE ARTERY.—When the loop of a ligature is drawn moderately tight upon an artery, the first effect produced will be to pucker and infold the arterial wall (Fig. 32). When the knot is tightly

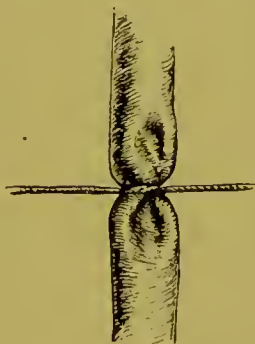


FIG. 32.—Action of the ligature upon an artery when the loop is drawn moderately tight. If just a little further traction be made the internal coats give way.

tied it invariably divides the inner and middle coats, which then slightly retract and turn inwards towards the lumen of the vessel, leaving only the external cellular envelope of the vessel, which is never divided, included in the noose, its internal surface being brought into close contact. The

vitality of the internal and middle coats is not impaired by their division, which is almost as sharply defined (Fig. 33), as if it were done with a knife, but that of the external coat may be. It is tightly constricted, and when

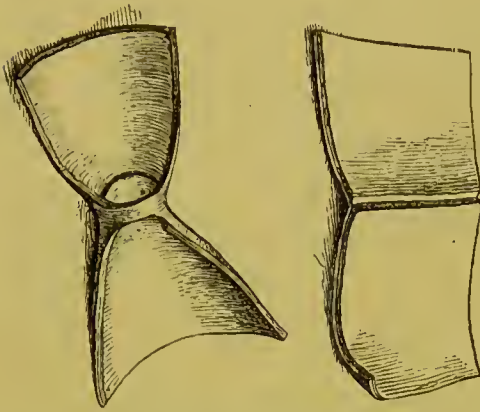


FIG. 33.—Showing the appearances presented by the vessel when laid open after division of its internal coats by the ligature. The noose has been removed.

the wound does not heal by first intention, the portion of the vessel included in the grasp of the ligature will come away as a small slough with the ligature at a subsequent period (Fig. 34). When the ligature is left with one end hanging out of the wound, the loop separates by a process of ulceration, a process which may extend from ten to sixty days, or even longer, and the healing of the external wound is necessarily delayed. The patient is thus not only exposed to the risk attendant

on all open wounds, but the obliteration of the vessel is liable to be less complete, and secondary hæmorrhage becomes a very frequent and even fatal complication. The use of an absorbable ligature material, and closure of the external wound with antiseptic precautions, obviate these undesirable results. The portion of the adventitia included in the noose does not lose its vitality, while by cutting off both ends of the ligature, closing the external wound, and applying a suitable form of dressing, we exclude the chances of septic change, and permit a more thorough organization of the plastic lymph that seals the ends of the vessel.

Very soon after the application of the ligature a clot forms in the artery above and below as far as the nearest lateral branches (Fig. 35). The clots which form in the artery above and below the point of ligature are not in any sense necessary for its obliteration. The obliteration of the artery takes place independently of their presence, and their formation is by no means so constant as is commonly supposed. They doubtless favour the process of repair by interposing a protection against the force of the blood current, and affording a medium in which the process of repair proceeds. Mr. Travers established the non-essential nature of the clot by his experiments on dogs and horses. He purposely applied the ligature

in some cases near to a large collateral branch, and although no clot formed, the vessel was safely obliterated. When, as Fig. 36 shows, the ligature has been applied near to the point of emergence of an important branch, a clot does not form on that side, or only to a very limited degree, but the artery is none the less obliterated. It is, however, desirable, whenever practicable, to avoid applying the ligature to a vessel in immediate proximity to a large branch.



FIG. 34.—Separation of the ligature. The noose has brought away a small portion of dead external coat. The patient was one of Mr. Cline's, who had successfully tied the external iliac artery for femoral aneurism. The ligature came away on the seventeenth day. The patient made a good recovery. (St. Thomas's Hospital Museum.)

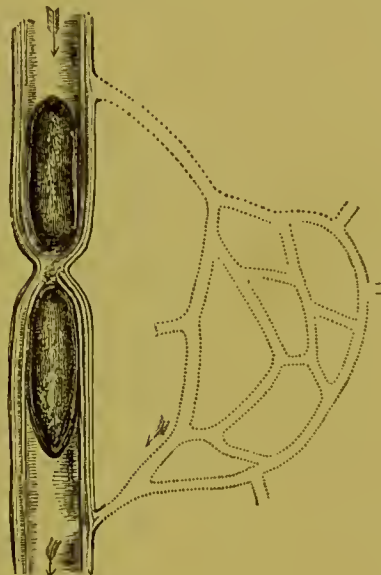


FIG. 35.—Diagram showing the clot formed above and below the point ligatured, and formation of the collateral circulation.

The vessel is obliterated by the organization of the lymph which is poured out in and around the artery, as a consequence of the injury done to the coats. Lymph is effused in the neighbourhood of the ligature around the divided margins of the inner and middle coats, between and within these coats, as well as outside the vessel. When the conditions for healing in the external wound are favourable, quite similar changes go on, whether after a simple wound of the artery, or after torsion of the vessel, as after its ligature.

If the steps of the process be observed in an animal, as for instance after ligature of one of the main arteries in a dog, it is found, when

twenty-four hours have elapsed, that a clot will have formed in the proximal portion of the vessel as far as the next collateral branch, that the internal coat is already slightly swollen, and continues to increase in thickness during the next three or four days by multiplication of its cell elements. By the eighth day buds of granulation material may be seen projecting from the surface of the inner coat, being especially well marked near the place of ligature (Fig. 37).

From the twelfth to the fifteenth days they invade the clot, appearing on transverse section like circles (Fig. 38) composed of cells held together by a

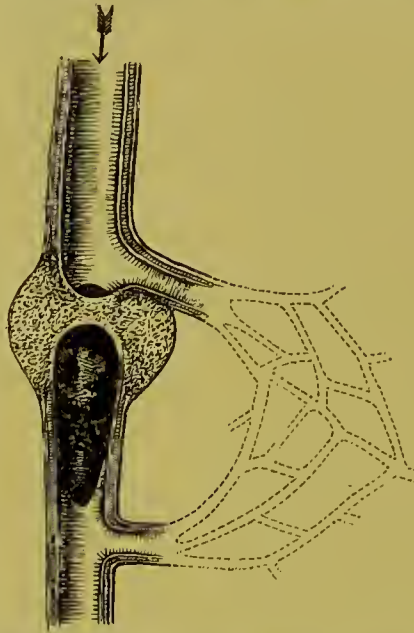


FIG. 36.—Diagram illustrating the action of the ligature when applied near to a lateral branch. There is a very small clot formed above. Below, a larger one occupies the lumen of the artery up to the next branch. Plastic material fills the space around the ends of the divided vessel. The dotted lines illustrate the mode of production of the collateral blood channels.

delicate connective tissue containing distended capillaries, and separated from one another by an intervening layer of blood-clot. At the portion of vessel wall with which these granulation masses are connected the middle coat of the artery is found by this time to have disappeared, and the vasa vasorum of the external coat appear to have become continuous with those newly formed in the interior of the vessel.

Finally, the granulations merge into one mass, and the clot disappears, save a few white globules and the débris of some red ones. The obli-

teration of the artery after ligature is therefore accomplished by the new material thrown out as the result of a local traumatic arteritis, and the coagulum is absorbed and replaced just as an extravasation into tissues outside the blood-vessels is removed. Similar changes occur on the distal side of the ligature, but here the formation of the thrombus is not so prominent a factor.

In the external wound made to expose the vessel, healing takes place in the soft parts immediately around the artery as it would after any similar

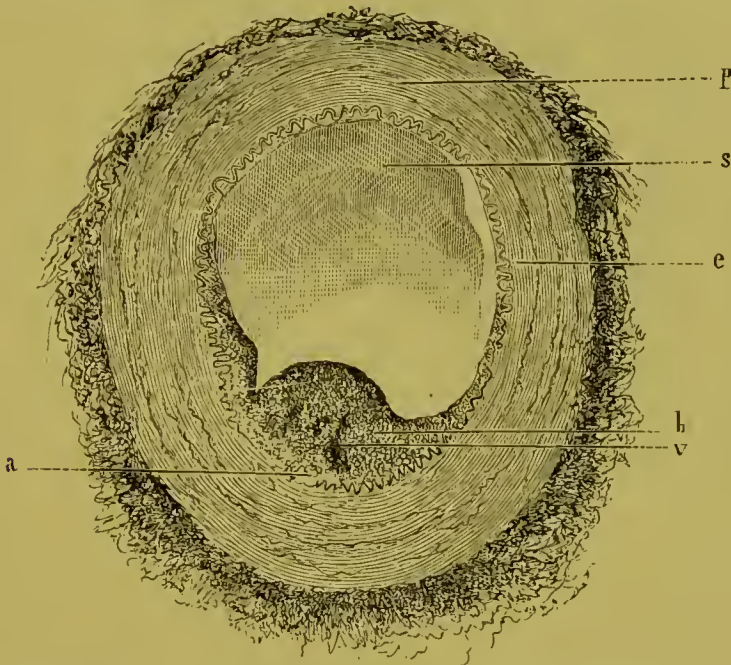

FIG. 37.—Transverse section of the femoral artery of a dog eight days after ligature. Cornil and Ranvier. *e*, Internal elastic lamina limiting the middle coat. *p*, Middle coat. *b*, Granulation mass springing from the internal coat. *v*, Newly formed vessels entering the granulations. *a*, At this point the internal elastic lamina is in part replaced.

form of injury. From the adventitia itself and the adjoining vascular tissues plastic material is poured out in the form of a broad ring or fusiform swelling for some distance above and below the point ligated. The plastic matter effused into the deeper parts of the wound speedily blends by vascular connecting loops with the new formation already described within the vessel, and at last cicatricial changes occur which transform a greater or less length of the artery into a solid fibrous cord. Every effort

must be made to secure thorough and rapid repair by keeping the wound in an aseptic condition.

During the time this process is going on the blood is seeking its way by other channels of communication to the distal portion of the limb. The

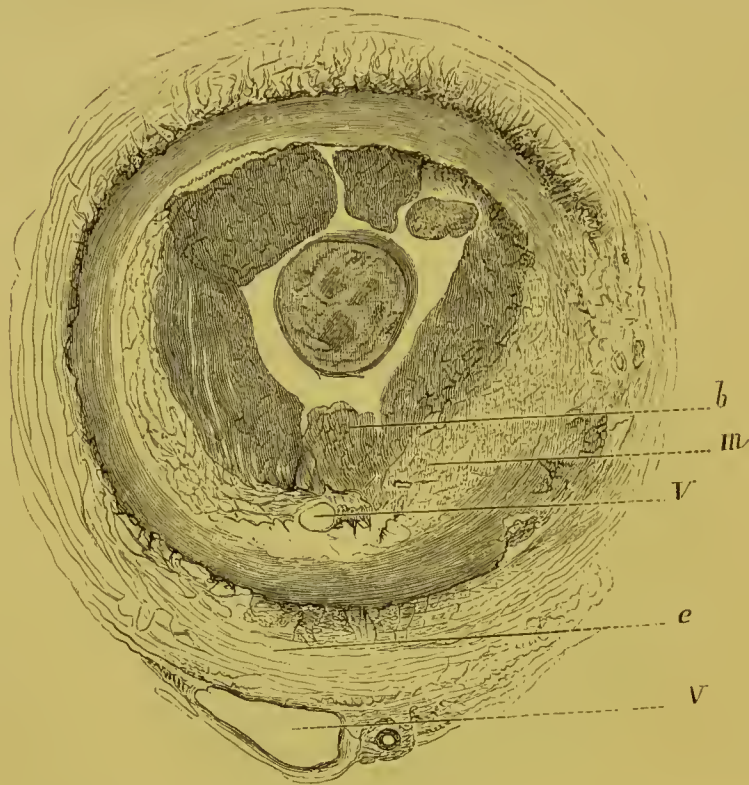

FIG. 38.—Transverse section of the carotid artery of a dog fifteen days after ligation : 15 diameters. Cornil and Ranvier. *b*, Granulation buds springing from the internal coat. One of these granulations is seen in transverse section in the centre of the figure. *m*, Middle coat as altered by inflammatory changes. *e*, External coat. *v v*, Transverse section of vessels, some seen in the altered internal, others in the external coat.

collateral branches enlarge, and the circulation becomes gradually re-established (Figs 35, 36).

With some surgeons it is even now a question, as it was in Scarpa's day, whether or no it is either desirable or necessary invariably to divide the internal and middle coats by the ligature. Indeed, the former practice of applying broad ligatures and thus compressing without dividing the wall of the vessel, has been reverted to in some instances. The practice of constricting the vessel without dividing the coats has probably a

better chance of success now than formerly, as absorbable material is used. Thick catgut, if not tied too tightly, will not divide the inner coats. The external wound may be closed; but the result can scarcely be so certain; the inner surfaces of the arterial wall become glued together, but if the ligature be too soon absorbed, it is doubtful if the closure of the vessel will be definitive, as is occasionally observed after acupuncture, where the occlusion is effected in a similar manner. It is urged that secondary hæmorrhage will be less frequent, but I think the common practice of using a small round ligature, and completely dividing the internal and middle coats, is, on the whole, much the better one. The injury done to the intima by its division is of cardinal importance for the formation of thrombus and the development of adhesive inflammation. A larger quantity of lymph will be poured out, there will be less likelihood of the circulation through the vessel becoming re-established, and in regard to the prevention of secondary hæmorrhage, once so frequent, strict antiseptic treatment has proved the most efficient safeguard.

There is now no longer the formerly well-founded dread of the disturbing influence of foreign dead material in the wound, including, as it necessarily does, an integral portion of the vessel wall, which must be cast out before the wound can close. In a wound which is maintained in an aseptic condition, catgut ligature, when used, is by degrees replaced by living cells without causing any local disturbance. Silk or hemp ligatures may also remain for an indefinite period without producing irritation, but frequently after remaining encapsuled for a time, a small abscess forms, and they are thrown off.

Professor Physick in 1814 first introduced the use of ligatures made of animal substance, the advantages claimed being at that time, as at the present, that the knot of animal matter left in the wound, while serving to obliterate the artery, afterwards becomes absorbed, and will not act as a foreign body in the wound. It was a dread of the consequences of the prolonged presence of a foreign body in the wound which led Jones, in 1806, and after him Travers and the surgeons of the time, to adopt the expedient of temporary deligation. A ligature was applied for a limited period to the artery and then removed, and the external wound closed. In the horse and dog these experiments

were often very successful, as is shown by specimens in the museum of St. Thomas's Hospital, but in man the practice proved disastrous, and was very soon abandoned.

For similar reasons various forms of the *presse-artère* have been invented, and their adoption was periodically advocated since the instrument was first introduced by Deschamps as a means of averting secondary hæmorrhage. Their action must be uncertain. Some are not intended to divide the inner coats, others are. But in all cases a foreign body is left for a time in the wound, which is a very serious objection.

The employment of prepared catgut has completely put to one side the possible risks which induced surgeons to resort to temporary ligatures, and the application of the *presse-artère*. In an aseptic wound a properly prepared catgut ligature applied to the artery becomes quickly absorbed, the wound closes, and all the objects for which the temporary deligation or compression was recommended are achieved without entailing any of the obvious disadvantages of these procedures. Chromicised catgut is the best variety to employ. It must be of a proper thickness. It does not become too speedily absorbed, and will hold firm for a period of three weeks—an interval amply sufficient for repair to take place. The ligature, properly applied divides the internal coats, whose edges are corrugated and infolded, thus permitting the opposite surfaces of the adventitia to be brought into contact with each other and unite directly by adhesive inflammation. The changes already described take place in the inverted intima and media, and the whole is presently blended into one mass of cicatricial tissue, the ligature gradually disappearing in the midst of it, without probably the formation of a single drop of pus. What a contrast this is to the former process of separation of the ligature after perhaps weeks of suppuration.

CHANGES WHICH TAKE PLACE IN THE SAC AFTER THE ARTERY HAS BEEN TIED.—When the blood current through an aneurism has been more or less completely arrested by the application of a ligature, the sac at once decreases in size, becomes less tense, and pulsation ceases. The resilience of the surrounding parts compresses the tumour. The interior is filled with clot, usually firm and laminated in the peripheral portion, while the central part is generally soft and amorphous (Fig. 39). As the fluid matter is absorbed

the clot by degrees shrinks, becomes firmer, and at the same time the sac contracts and the tumour becomes hard. As organization proceeds in the interior, so does the sac diminish in size, until the contents are gradually completely removed, and a fibrous cord (Fig. 41) is all that remains to represent the former aneurism and the vessel on which it was placed, for

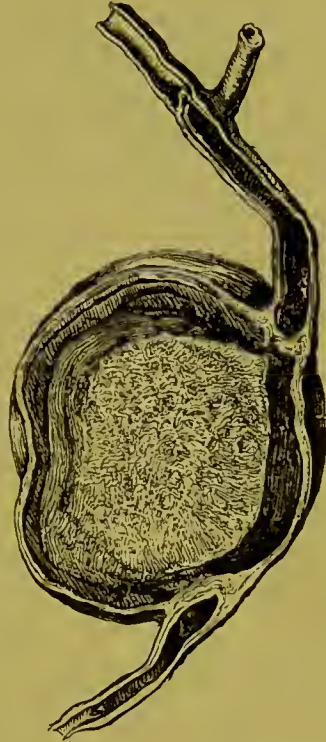

FIG. 39.—Section of a femoral aneurism apparently cured after the application of Esmarch's bandage, followed by digital compression, by Mr. Clutton. The exterior is composed of firm clot in layers, while the interior is soft and spongy. The patient, a young man of thirty-four, died suddenly, seven weeks after the ligature, from rupture of a small aortic aneurism into the pericardium. Although all pulsation had ceased, and the tumour continued to shrink in size, it was noticed in a few days that its contents were partly fluid, and they remained so to the last. On removal, after death, the greater portion of the sac was found filled with recent post-mortem clot, the femoral artery above the tumour obliterated by a firm, adherent, and a partially decolorized coagulum, extending as far as the nearest branch.

some distance above and below the aneurism. Many months may be required to complete these changes.

COLLATERAL CIRCULATION.—Through the enlargement of the adjacent arteries the collateral circulation begins to develop the moment the main

current is arrested. In animals it is very rapidly established. In man the time varies. The restored pulse has been felt below the sac in the radial or tibial arteries almost immediately, or in a day or two after the ligature. Sometimes its reappearance is very long delayed.

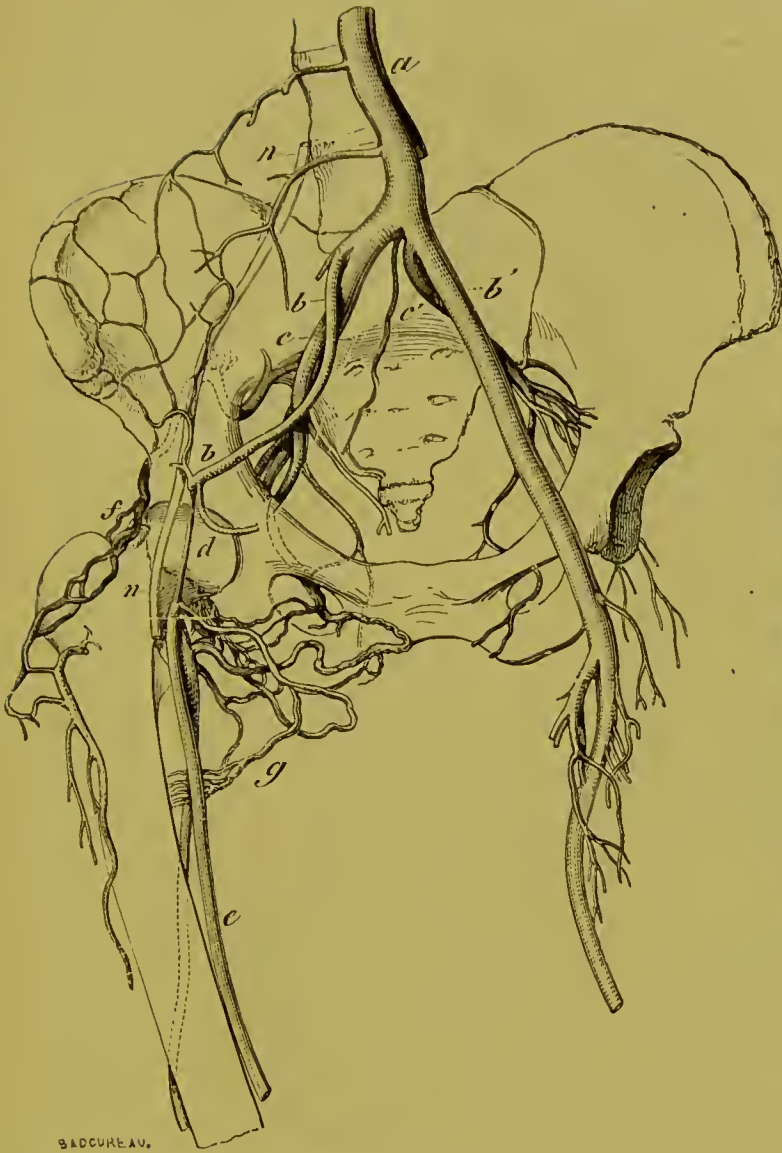The first effects of ligature are to induce pallor and diminished heat of the parts supplied. These are succeeded in a few hours by a slight blush, and even increase of temperature; the normal appearance and heat of the part being then gradually regained. Either of these conditions, in an exaggerated degree, may put the limb in danger of gangrene.

The establishment of an efficient collateral circulation is largely dependent on the state of the general vascular system. As a rule, it is to be most confidently expected in young patients, in whom the circulation is presumably good. In older persons, or those whose arteries are much diseased, the collateral current will be created with greater difficulty and more slowly.

Generally a large number of vessels take part in conveying the blood (as seen in Figs. 40, 41, 42*). Sometimes only one has been found. This circumstance is illustrated by a specimen in the Museum of St. Thomas's Hospital, where the brachial artery had been tied (Fig. 42).

As a rule, the nearer the point ligatured is to the centre of circulation, the more rapidly and effectively will the collateral current of blood be established, the blood pressure being proportionately greater. But this, while it renders gangrene less frequent, predisposes to the occurrence of secondary hæmorrhage.

AFTER-TREATMENT.—Promote the immediate union of the external wound. Maintain the part completely at rest, and if an extremity, in a slightly flexed position. The limb should be raised, to favour the return flow of the current of venous blood. Apply external heat, which should be secured by warm water vessels (the temperature of the water should not exceed 100° F.), and envelop the limb with cotton wool and flannel bandages, taking great care that no constriction takes place anywhere. If heat be applied incautiously, or if the bandages applied round the limb exert compression, there is considerable risk of gangrene, owing to the enfeebled condition of the circulation.



SADOURÉAN.

FIG. 40.—Collateral circulation after the ligation of the right common femoral artery. *a*, Abdominal aorta *b*, Right external iliac artery. *b'*, Left external iliac. *c*, Right internal iliac. *c'*, Left internal iliac. *d*, Fibrous cord, representing the portion of artery ligatured. *e*, Lower portion of right femoral. *f*, Dilated anastomosing branches of the gluteal artery. *g*, Dilated anastomosing branches of the obturator artery. *n*, Crural nerve.—Musée Dupuytren.

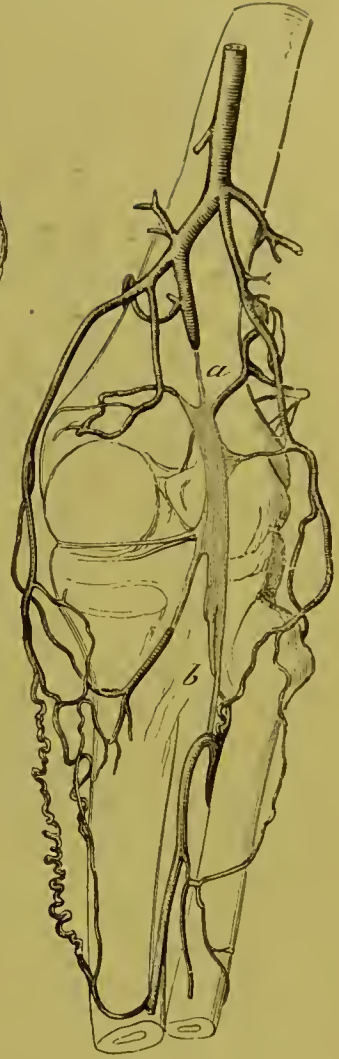


FIG. 41.—Collateral circulation established after the cure of a popliteal aneurism. *a*, *b*, Remains of popliteal artery and aneurism transformed into a fibrous cord. On the inner side of the limb the circulation is mainly carried on between the superior internal articular artery above and the inferior internal articular below. On the outer side between the superior external articular above and the recurrent articular branch of the anterior tibial artery below.—Musée Dupuytren.

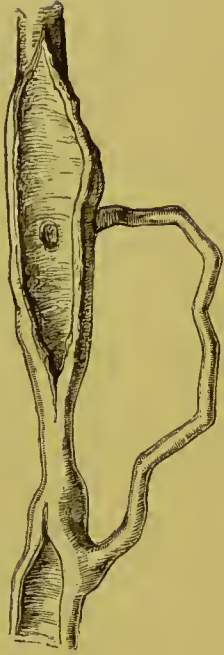


FIG. 42.—Ligature of the brachial artery. Only one collateral branch was found on dissection afterwards. The artery is completely obliterated by fibrous tissue. A tortuous collateral vessel emerges from the artery an inch above the seat of ligature and re-enters it half an inch below.—St. Thomas's Hospital Museum.

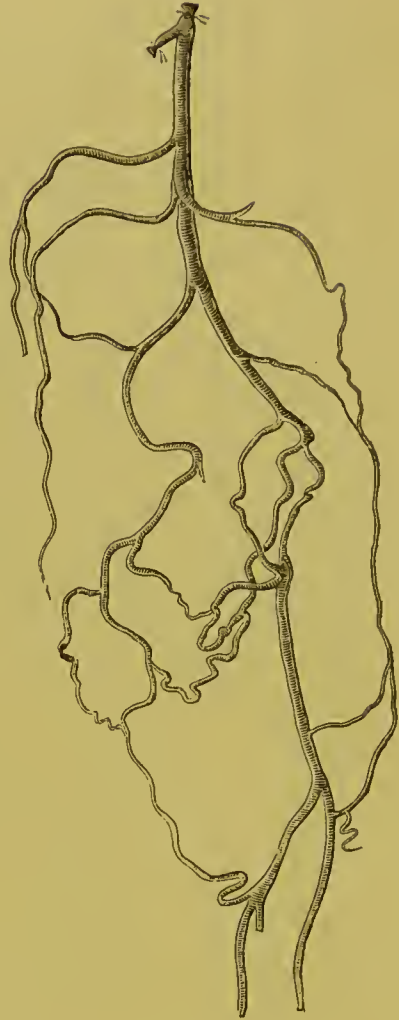

Fig. 42*.—Collateral circulation after ligation of the right brachial artery. The vessels appear to be chiefly enlarged muscular branches to the biceps and triceps. The single trunk below is the brachial artery passing down to divide into the radial and ulnar artery. At the middle part, where three small vessels are seen, the ligature was applied. The upper vessel on the left side is probably

the superior profunda, below is the inferior profunda, which forms a loop with a vessel given off immediately after the brachial has reappeared. The loop also receives one of the three branches already named, and a recurrent branch from the ulnar artery.—St. Thomas's Hospital Museum.

Prolonged rest both to the part and to the body generally must be given in order to permit of consolidation and organization of the clot and of the plastic matter poured out at the seat of ligature, as well as to allow absorption of the contents of the aneurismal sac to take place.

CAUSES OF FAILURE AFTER LIGATURE.—A *vas aberrans* may be present and the pulsation in the sac but little or not at all controlled by the ligature of what appears to be the main trunk. The circulation in the aneurism, temporarily abolished by the operation, may, in some cases return in a few hours or days afterwards. A slight recurrent pulsation on the second or third day is not uncommon. It is transient as a rule, and probably renders the formation of firm laminated clot more probable. Sometimes a recurrence of pulsation in the aneurism will be felt after an interval of four or five weeks, which, after a short continuance, generally disappears. Recurrent pulsation may also show itself even when an apparent cure has taken place for two, three, or more months. The probable explanation is the breaking down of a faulty coagulum, and over-abundant blood supply. The blood again reaches the sac, by which time the collateral circulation has been fully established, and there is much less chance of ultimate cure. Finally, the disease after a temporary arrest may progress unaffected by the previous ligature, an untoward result due to preternatural activity of the collateral circulation.

Recurrent pulsation has been very often observed after ligature for carotid aneurism, and is doubtless dependent for its comparative frequency in this and some other regions, on the ease with which the collateral circulation becomes established. Rest, pressure, cold locally applied, may be tried. If these fail, the operation of Antyllus, ligature of the vessel at some higher point, or even amputation may have to be resorted to.

In some cases the continuity of the vessel becomes re-established after ligature, and the object for which the operation has been performed is not attained. If the ligature fail to obliterate the vessel, as has happened with catgut ligatures which have become too soon absorbed, and the circumstances of the case demand further interference, the vessel may be tied again at some higher point.

COMPLICATIONS AND CAUSES OF DEATH AFTER LIGATURE.—The principal complications which may occur after the ligature of an artery

in its continuity are secondary hæmorrhage, and gangrene of the limb supplied by the ligatured vessel. Inflammation and suppuration sometimes take place in the sac, an accident not infrequent in axillary aneurisms. The period after ligature at which this ensues varies. The sac increases rapidly in size, becomes tense, red, and painful, the skin thins, and the tumour may burst. The sac must be laid open and the contents turned out. If bleeding do not occur, or if the bleeding points can be secured, a satisfactory result may follow. If the hæmorrhage cannot be restrained or if it recur with violence or frequency, amputation, where practicable, should at once be performed.

Gangrene of the parts beyond the point of ligature is a frequent accident, and often proves fatal, either through septic infection, or from the amputation it subsequently entails. Gangrene occurring in the lower extremity is more fatal than in the upper. It is most likely to occur after ligature for aneurism in the lower extremity. It is not so frequent in the upper limb because of the free anastomoses which exist there. It is three times more frequent after ligature for secondary hæmorrhage than for aneurism. It occurs, as a rule, within the first forty-eight hours, and if during this period there be no distinct evidence of impaired vitality in the limb, the probability of its later occurrence is slight. It may, however, show itself either within the first twenty-four hours, or so late as the eighth day. Gangrene may be limited in extent, and slow in progress, or so rapid as to involve the entire limb below the seat of ligature in a few hours. In the former case it will be proper to await the formation of a demarcating line, but in extensive acute gangrene, which is the usual kind, septic absorption may take place, and early amputation will be the proper course to adopt. Acute gangrene usually depends on the tardy or imperfect establishment of the collateral circulation, injury and obliteration of the principal vein in addition to the artery, exposure to cold, the application of too great heat, or secondary ligature of the artery at a higher point. When this unfortunate accident takes place the limb should, as a rule, be amputated opposite the place of ligature without waiting for a demarcating line to form.

Secondary hæmorrhage is less common, and since the general adoption of antiseptic precautions and the catgut ligature, it has become compara-

tively rare. The nearer the vessel tied is to the heart, and the larger its calibre, the more likely will this accident be to happen. It is more frequent in the upper half of the body than in the lower, and after ligatures applied for disease than for a wound. It is apt, in some instances, to recur repeatedly. This is evidence of an abundant collateral circulation, and more likely to follow in those situations where the anastomoses are numerous. The period of its occurrence varies from a few days to six or eight weeks. Secondary hæmorrhage has been especially frequent after ligature of certain vessels, as, for instance, after the ligature of the common femoral, axillary, carotid, and subclavian arteries. When it takes place, it is always formidable, and often may prove fatal. If local compression do not arrest it, an attempt should be made to secure the vessel by ligature at the bleeding point. If this be impracticable, amputation will frequently become necessary; although in a few cases the artery may be successfully tied at some higher point. In the lower extremity, however, gangrene will be very likely to follow this practice. Formerly, when silk ligatures were in general use, secondary hæmorrhage was apt to occur at the time of separation of the ligature. From the tenth to the fifteenth day used to be a common date for it to happen. The early detachment of the ligature, suppuration taking place around it, and the nearness of some important collateral branch, are frequent causes of secondary hæmorrhage. The immediate cause of the bleeding is perforation of the vessel wall in close proximity to the ligature, by changes most probably provoked by its presence. Either the thrombus or the plastic organization is not sufficiently resistant or consolidated, or the wound has suppurated. Violent movements, by tearing asunder recent adhesions, account for some cases, as fits of severe coughing after ligature of the vessels in the neck. The bleeding may occur either from the upper or lower end, or from both ends of the tied artery. After the ligature of the superficial femoral in Scarpa's space it comes chiefly from the upper end, where the external iliac has been tied from the lower end, and after ligature of the common femoral from both ends. An effort should be made in these cases, when pressure fails, to secure both extremities of the artery in the wound above and below the bleeding point. If this do not succeed, the vessel may be tied again at a point nearer to the heart. The final result is too often unsatisfactory.

LIGATURE OF THE ARTERIES OF THE UPPER EXTREMITIES, NECK, FACE, AND HEAD.

ARTERIES OF THE HAND.

Indications for Treatment.—The digital arteries are often wounded. They are not large enough to occasion any very great trouble in arresting bleeding from them. Pressure usually suffices.

The only artery of moment that can be wounded on the back of the hand is the radial, as it winds round the outer side of the carpus and base of the first metacarpal bone to reach the upper end of the first interosseous space (Fig. 45). It is here nearly parallel to the radial extensors, crosses beneath the extensor muscles of the thumb, and then passes between the heads of the abductor indicis. It may occasionally have to be ligated for a wound.

The vessels in the palm of the hand may require ligature either on account of accidental wound, injury during the incision of a whitlow, or in some other surgical operation.

Wounds of the deep and superficial palmar arches are not uncommon, and are of great surgical importance. The hand, the arm, or even the life of the patient, has been occasionally sacrificed as the consequence of such an injury. The temptation to rely on local pressure to arrest the hæmorrhage in place of discovering the bleeding vessel, by what may prove a troublesome dissection, frequently results in secondary hæmorrhage taking place, recurring again and again, often complicated with suppuration, septic changes in the wound, and subsequent general infection. Suppuration is liable to extend along the sheaths of the tendons, and may cause permanent impairment of the functions of the hand. If the wound in the hand be large enough, an attempt should be made to secure the bleeding points, or the wound may be enlarged for the purpose.

When wounded, the palmar vessels should be tied, if possible, at the seat of injury. Graduated pressure may often arrest the hæmorrhage, temporarily at all events, but the free anastomoses render it very apt to recur, and by that time inflammatory changes in the soft parts make the artery much more difficult to find, and less easy to ligature.

Punctured wounds, especially if they involve the deep arch, should be treated by local graduated pressure and elevation of the limb. Complete flexion of the elbow-joint is a valuable means, and if maintained for forty-

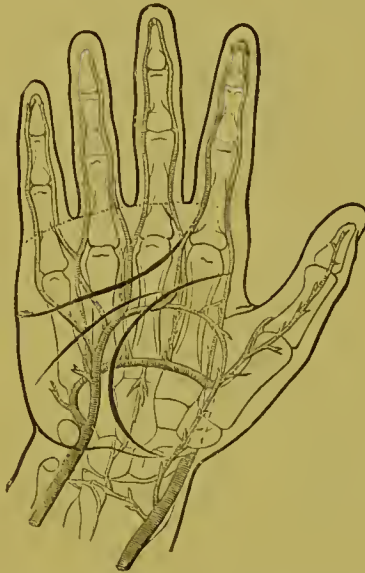

FIG. 43.—The figure is intended to illustrate the position and mode of formation of the palmar arches, and distribution of the digital arteries.

eight or seventy-two hours, will often suffice to permanently arrest bleeding from wounds of the palmar vessels. Should these methods fail to arrest the hæmorrhage, and a search for the bleeding points in the wound prove unsuccessful, ligature of the arteries in the forearm, or of the brachial artery may become necessary. Incised or lacerated wounds of the hand admit, as a rule, of the bleeding vessels being secured in the ordinary way in the wound itself.

Owing to their close proximity it may be very difficult to tell whether the hæmorrhage comes from the superficial or deep arch. In such a case alternate compression of the radial and ulnar arteries at the wrist, and also the position and direction of the wound may aid the diagnosis. Liga-

ture of the ulnar artery may be performed for a wound of the superficial arch, especially if the bleeding can be checked by compression of that vessel. When it comes from the deep arch the radial artery may be tied.

SUPERFICIAL PALMAR ARCH.

Indications.—Punctured, incised, lacerated, and gunshot wounds. Injury to the vessel during the incautious incision of a whitlow. Traumatic aneurism.



FIG. 44.—The figure shows the method of finding the position of the superficial palmar arch referred to in the text, and the direction and exact position of the wound which would have to be made in order to reach it.

Anatomical Relations.—It is necessary to know the exact position of the arteries of the hand, not merely in order to discover them when wounded, but for the equally important object of avoiding them when opening abscesses or seeking for foreign bodies in the palm. The superficial palmar arch is smaller than the deep arch (Fig. 43). It lies on the flexor tendons and median nerve, and is covered by the integuments and the palmar aponeurosis. Its direction corresponds to a curved line, convex downwards and inwards, drawn from the outer side of the pisiform bone to the angle between the thumb and index finger. Wounds of this vessel

bleed profusely. The superficial volar branch from the radial, which, when present, completes the superficial arch, is sometimes subcutaneous, but generally it runs through the substance of the muscles of the thumb.

Guide.—The central portion of a transverse line drawn across the palm from the angle of the web between the thumb and the index finger corresponds pretty accurately with the position of the middle of the superficial palmar arch. If the thumb be abducted, its anterior surface is (Fig. 44) continuous in direction with the palmar outline of the ball of the thumb, which will then become parallel to the "middle palmar fold." The vessel lies parallel to and equidistant between them.

Operation.—An incision one inch long (Fig. 44) made midway between and parallel to these lines, and nearly opposite to the bases of the middle and ring fingers, will readily expose the superficial arch in its thicker or ulnar portion, after the skin and palmar fascia have been divided.

DEEP PALMAR ARCH.

Anatomical Relations.—The deep palmar arch (Fig. 43) runs transversely across the junction of the bases with the shafts of the metacarpal bones, about half an inch higher up or nearer the wrist than the superficial arch. It is shorter, less curved, and runs more transversely than the superficial arch. Deeply placed beneath the superficial and deep flexor tendons, it is covered by everything in the palm except the interossei muscles.

Indications for Treatment.—This vessel is not so readily wounded as the superficial arch. It would be very difficult to secure *in situ*, as the wound made to reach it must be very deep, and would involve too many important structures. When pressure, both locally and on the brachial artery, combined with an elevated position of the extremity, fails to arrest the bleeding, the radial has been tied, but rarely with permanent good effect. It is probably preferable in most cases to ligature the brachial artery in the first instance. Between the tendons of the extensor primi and secundi internodii pollicis muscles (Fig. 45) [in the so-called *tabatière anatomique*] the radial artery has been occasionally tied for a wound of the deep palmar arch—an untrustworthy means, however, of definitively arresting hæmorrhage. Both radial and ulnar arteries may be tied close to the wrist, but this

also is uncertain in its result, as the interosseous artery, or an abnormal median artery, quickly supplies the blood again, and will probably necessitate ligature of the brachial artery.

LIGATURE OF THE RADIAL ARTERY.

Indications.—In cases of wound and aneurism requiring the operation, this artery may be tied in any part of its course. Spontaneous aneurism is exceedingly rare. Traumatic aneurisms are sometimes observed.

Guide.—The vessel is in direct continuation with the course of the brachial artery. Its general direction corresponds to a line drawn from the centre of the fold of the elbow, or midway between the condyles of the humerus and just internal to the biceps tendon, to the front of the styloid process of the radius. The internal border of the supinator longus muscle forms a good guide to the vessel in the upper half of the forearm.

Surgical Anatomy.—The radial artery (Fig. 49) is smaller than the ulnar at its origin. It passes along the radial side of the forearm from the bifurcation just below the middle of the bend of the elbow to the front of the styloid process at the wrist, where it winds backwards round the outer side of the trapezium beneath the extensor tendons of the thumb, and then passes forward into the palm, between the heads of the first dorsal interosseous muscle, to form the deep palmar arch. It is accompanied by venæ comites, which are united by cross branches.

The artery is accessible throughout, being covered only by skin and fascia, except above, where it is overlapped by the supinator longus. It lies first on the biceps tendon, and then, in succession, on the supinator brevis, pronator teres, flexor sublimis, flexor longus pollicis, and pronator quadratus muscles, and the lower end of the radius.

In the upper third of its course it lies between the supinator longus and pronator radii teres muscles; in the lower two-thirds, between the tendons of the supinator longus and flexor carpi radialis. The radial nerve is in somewhat close external relation with the artery in the middle part of its course only. Below this point it has passed beneath the supinator longus, and is at some distance from the vessel.

LIGATURE OF THE RADIAL ARTERY IN THE TABATIÈRE ANATOMIQUE.

Guide.—On the dorsal surface of the carpus the artery (Fig. 45) crosses the depression between the extensor tendons of the thumb (*tabatière anatomique*). The radial vein overlies the deep fascia, and may be mistaken for the artery: the artery is beneath it, and only covered by the skin, superficial and deep fascia.

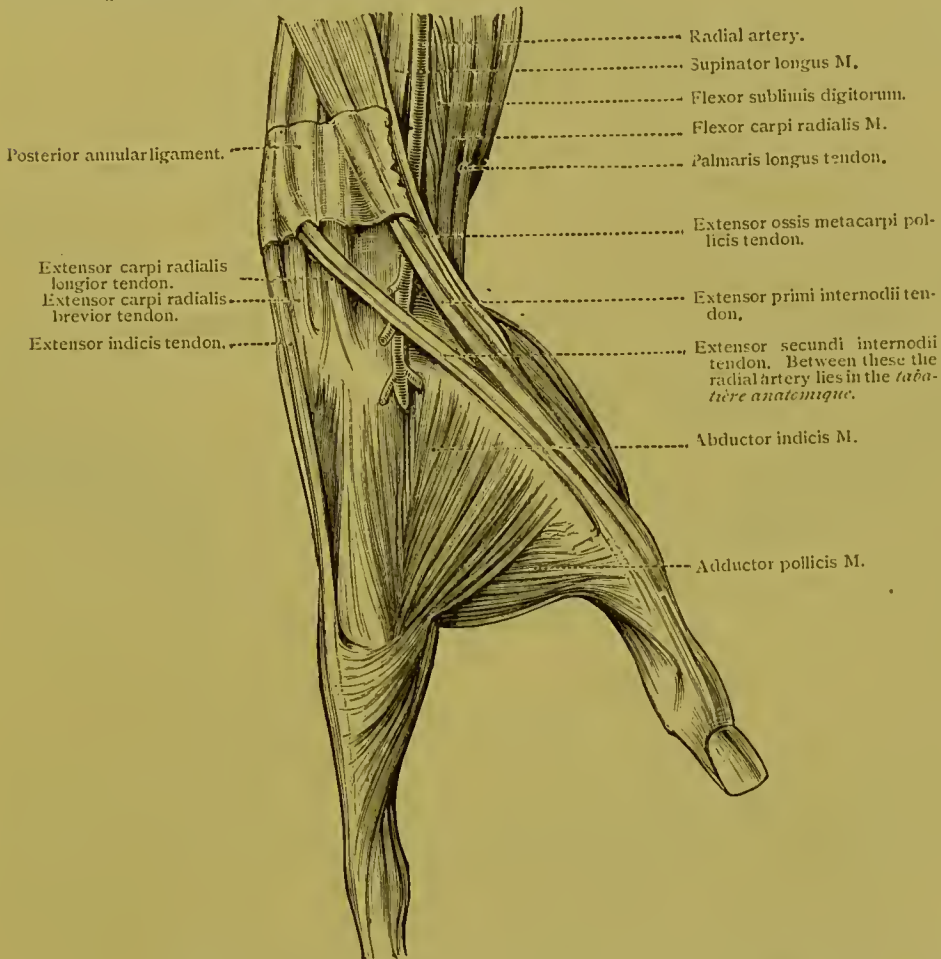


FIG. 45.—Radial artery as it passes round the outer border of the carpus beneath the extensor muscles of the thumb.

Operation.—Extend and abduct the thumb. Make an incision, one inch or one inch and a half long, parallel to the tendons, in the mid-space between them. Divide the skin and fasciæ. The artery will then be easily exposed. Separate it from the veins. It is a matter of indifference from which side the needle is passed.

LIGATURE OF THE RADIAL ARTERY IN THE LOWER THIRD.

Surgical Anatomy.—In the lower third of the forearm the artery is covered by skin and fascia only, and lies along the inner border of the supinator longus tendon. It is accompanied by two veins with cross branches which should not be included in the ligature. If they be, however, no evil consequences will ensue. The nerve is external and so far distant as to be quite out of the field of operation.

Guide.—The radial border of the flexor carpi radialis tendon.

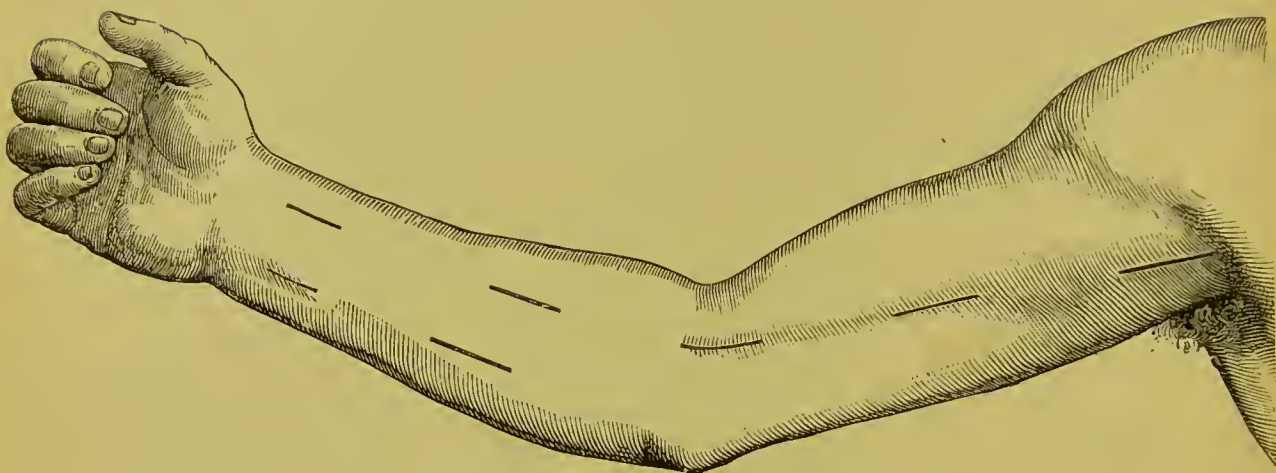


FIG. 46.—Position of some of the superficial incisions made for deligation of the arteries of the arm and forearm.

Operation.—Make an incision (Fig. 46) nearly two inches long, parallel and just external to the flexor carpi radialis tendon, which forms the best guide. After the aponeurosis of the forearm is divided the artery will be easily found. Separate the veins from the artery. The needle may be passed from either side.

LIGATURE OF THE RADIAL ARTERY IN THE MIDDLE THIRD.

Surgical Anatomy.—In the middle third of the forearm the artery is rather deeper than in the lower third. The nerve is somewhat close to the outer side.

Guide.—Line before named, and the outer border of the flexor carpi radialis muscle.

Operation.—Make an incision about two inches long (Fig. 46). Care must be taken not to injure or include the radial nerve, which is, however, about half an inch external to the artery. The operation otherwise is similar to that in the lower third. The incision must be made somewhat longer in proportion to the muscular development.

LIGATURE OF THE RADIAL ARTERY IN THE UPPER THIRD.

Surgical Anatomy.—The vessel with its venæ comites lies deeply between the inner border of the supinator longus muscle and the outer border of the pronator teres muscle. The nerve is external and distant.

Guide.—In the upper third of the forearm this will be the line before mentioned.

Operation.—The incision should be nearly three inches long, commencing an inch below the middle of the bend of the elbow. Divide the skin and fasciæ. Seek the intermuscular septum and draw the supinator muscle aside. In the interval between this and the pronator teres muscle, the artery will be seen. The needle should be passed from without inwards. The radial nerve, however, is not in close relation with the vessel. If the median nerve be exposed it should be carefully held aside.

LIGATURE OF THE ULNAR ARTERY.

Indications.—Wound, Aneurism.—This vessel may be easily tied in the lower two-thirds of its course. It is too deep to reach in its first part, where it is covered by the flexor muscles, except for a wound. Spontaneous aneurism is very rare.

Surgical Anatomy.—The ulnar artery (Fig. 49) is larger than the radial. It crosses obliquely to the inner side of the forearm from the point of bifurcation, and then passes along the ulnar border of the lower half of the forearm. It is covered in its upper half by the mass of the superficial flexor muscles, the flexor carpi ulnaris excepted—viz., the pronator teres, flexor carpi radialis, flexor sublimis and palmaris longus muscles, and is crossed by the median nerve. It lies at first on the brachialis anticus, then upon the

flexor profundus digitorum muscle. In the lower half of its course the artery is only covered by the skin and fasciæ, and lies on the radial side of the flexor carpi ulnaris muscle, between it and the flexor sublimis. The ulnar nerve is here quite close to the ulnar side of the artery. Venæ comites with cross branches accompany the vessel.

LIGATURE OF THE ULNAR ARTERY IN THE LOWER THIRD.

Guide.—A line drawn from the front of the internal condyle to the radial side of the pisiform bone along the radial border of the flexor carpi ulnaris tendon will correspond in direction to the lower two-thirds of the vessel.

Operation.—In the lower third of the forearm the incision should be

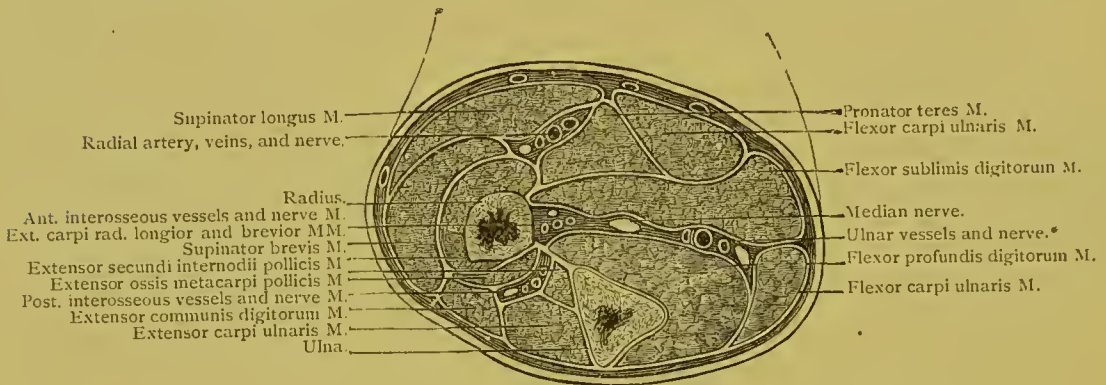


FIG. 47.—Transverse section through the middle of the right forearm.

nearly two inches long (Fig. 46). On dividing the skin and superficial fascia, the border of the flexor carpi ulnaris muscle will be seen. Divide the aponeurosis opposite the interval between the flexor carpi ulnaris and flexor sublimis muscles. Flex the wrist. Avoid opening the sheath of the flexor carpi ulnaris muscle. Draw the tendon of the latter inwards, the flexor sublimis outwards, and thus expose the vessel with its venæ comites, which should be separated from the artery. Pass the needle from the ulnar side, to avoid injuring the nerve, which is quite close.

LIGATURE OF THE ULNAR ARTERY IN THE MIDDLE THIRD.

Guide.—In the middle third of the forearm this will be the line previously mentioned.

Operation.—Incise the skin and superficial fascia for a distance of nearly three inches (Fig. 46). On exposing the deep fascia seek the interstice between the flexor carpi ulnaris and flexor sublimis muscles, which does not exactly correspond with the direction of the artery. (Fig. 49.) Along this line open the deep fascia, and separate the muscles, commencing below. The ulnar nerve is usually first seen. The artery is afterwards easily exposed and ligated.

In the upper third of the forearm ligation of the ulnar artery is a rejected operation, except for a wound of the vessel in this region. The artery lies very deep. To reach it the muscles attached to the internal condyle would have to be cut through.

LIGATURE OF BRACHIAL ARTERY.

Indications.—When requiring operation, usually either for a wound or injury, this artery may be tied in any part of its course. Aneurism of the vessel is very rare, except it be of the traumatic or varicose form. Wound of the artery at the bend of the elbow was not infrequent when venesection was a common practice. Anel was the first to tie the brachial artery for aneurism following an accident of this kind. He applied a ligature to the vessel just above the tumour, without making an incision into the sac, which was the common practice previously.

Surgical Anatomy.—The brachial artery runs a very superficial course along the inner aspect of the arm, and can be readily compressed against the humerus from within outwards above, and directly backwards at the elbow. It commences opposite the lower margin of the conjoined tendons of the latissimus dorsi and teres major muscles, and passing downwards and slightly forwards, terminates about half an inch or three-quarters below the centre of the fold of the elbow, a point corresponding in level to the neck of the radius (Fig. 49.)

The brachial artery, covered by skin and fascia, is overlapped by the edge of the coraco-brachialis above, and by the edge of the biceps muscle below. The median basilic vein lies in front at the lower part, and at the bend of the elbow the bicipital fascia separates the two vessels. Two satellite veins usually accompany the artery. On the

inner side of the artery, in the middle third of its course, are the basilic vein, ulnar and internal cutaneous nerves. To the outer side above are the median nerve (which crosses to the inner side about the middle of the arm) the coraco-brachialis and biceps muscles. Behind are, first, the long and internal heads of the triceps, between which dip the superior profunda artery and musculo-spiral nerve, the artery then lies upon the insertion of the coraco-brachialis, and, for the rest of its course, on the brachialis anticus muscle. The brachial artery frequently bifurcates high up, even as high as the axilla, and two main trunks will then run parallel and near to one another in the arm. About once in eight times the brachial artery is double in some part of its course. In such case, if only one artery be observed and ligatured, it

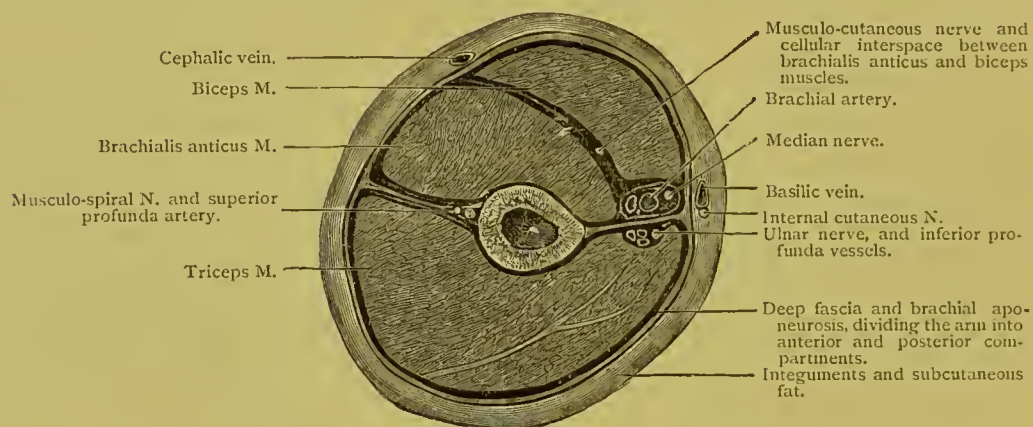


FIG. 48.—Diagrammatic section through the middle of the right arm.

may produce little or no effect upon the disease or injury for which the operation was undertaken. A second should then be sought for and operated upon.

Guide.—Abduct the arm, and supinate the forearm. A line drawn from the depression behind the axillary margin of the pectoralis major, which will be a little in front of the middle of the axilla, to the middle of the elbow-fold, indicates the direction of the artery. The inner margin of the biceps muscle in the middle and lower part of the arm, and that of the coraco-brachialis above will form a good guide. After the skin is incised and the superficial fascia and muscular aponeurosis divided, the sheath of the artery will be exposed when the muscles are retracted to the

outer side. The median nerve is easily felt, in thin persons, before the skin is divided, crossing the direction of the vessel.

LIGATURE OF THE BRACHIAL ARTERY AT THE BEND OF THE ELBOW.

Guide.—At the bend of the elbow, line before mentioned. Inner edge of the biceps tendon.

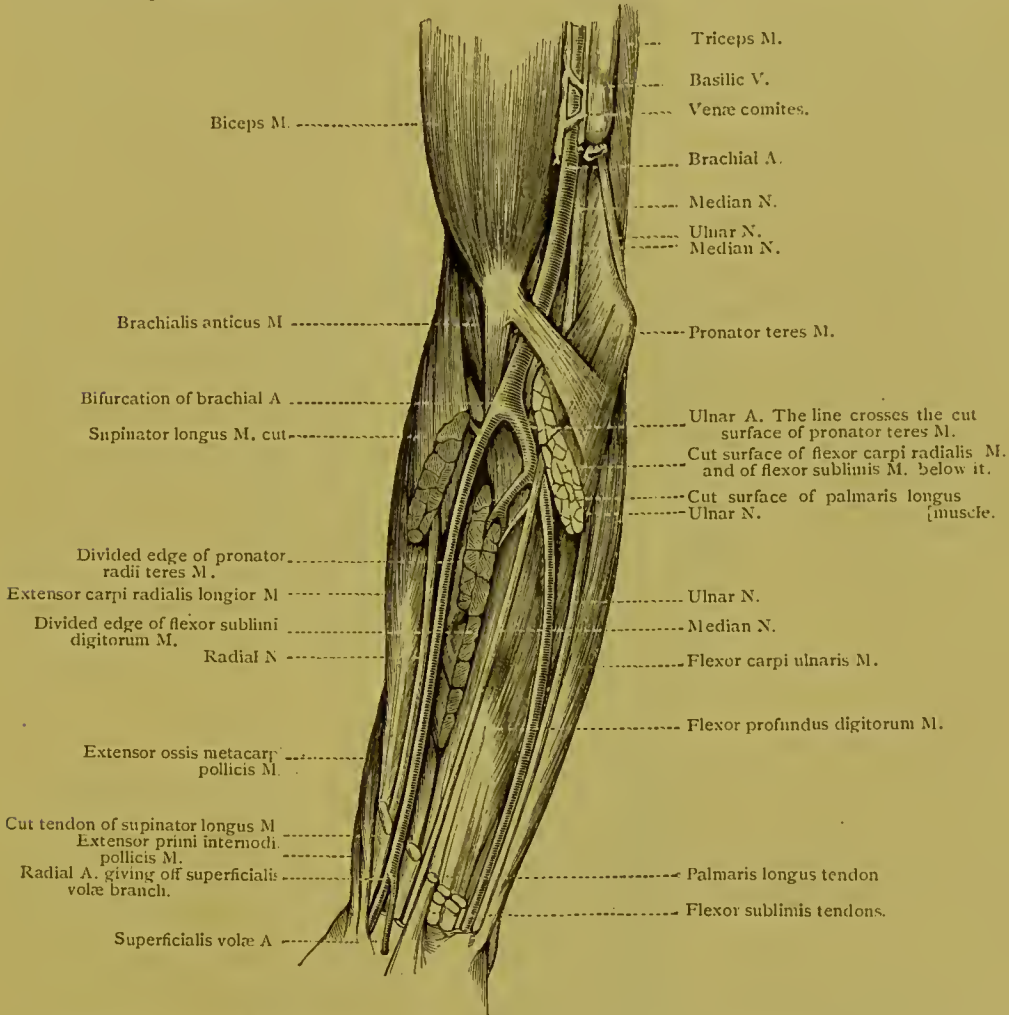


FIG. 49.—Surgical anatomy of the radial and ulnar arteries, and lower portion of the brachial artery.

Surgical Anatomy.—The vessel is very superficial, and was at one time frequently injured by the incautious use of the lancet in venesection. It lies between the tendon of the biceps on the outer side and the median nerve, which is nearly half an inch internal to the artery (Fig. 49).

Operation.—Make a slightly oblique incision (Fig. 46) in front of the elbow, parallel to the median basilic vein, and about two inches long. The incision should terminate below near the elbow-fold. Avoid

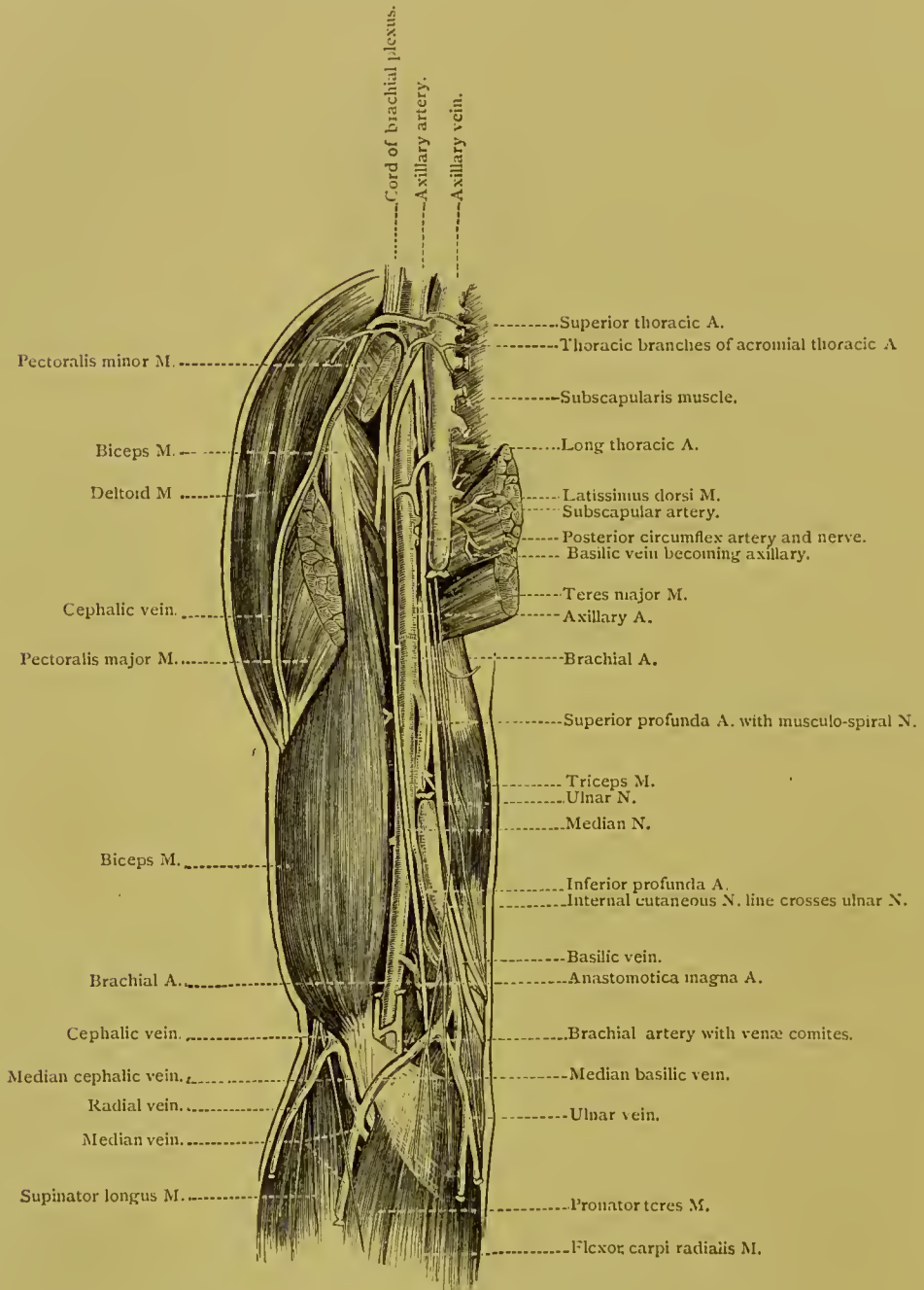


FIG. 50.—Surgical anatomy of the brachial artery.

injuring the median basilic vein, whose course corresponds with that of the artery at this point. Induce distension of the veins before dividing the skin, to indicate their position. Divide the oblique fibres of the bicipital fascia. The vessel surrounded by fatty tissue will then be exposed between its venæ comites.

LIGATURE OF THE BRACHIAL ARTERY IN THE LOWER TWO-THIRDS OF THE ARM.

Guide.—In the lower two-thirds of the arm, line before mentioned, and the edge of the biceps muscle.

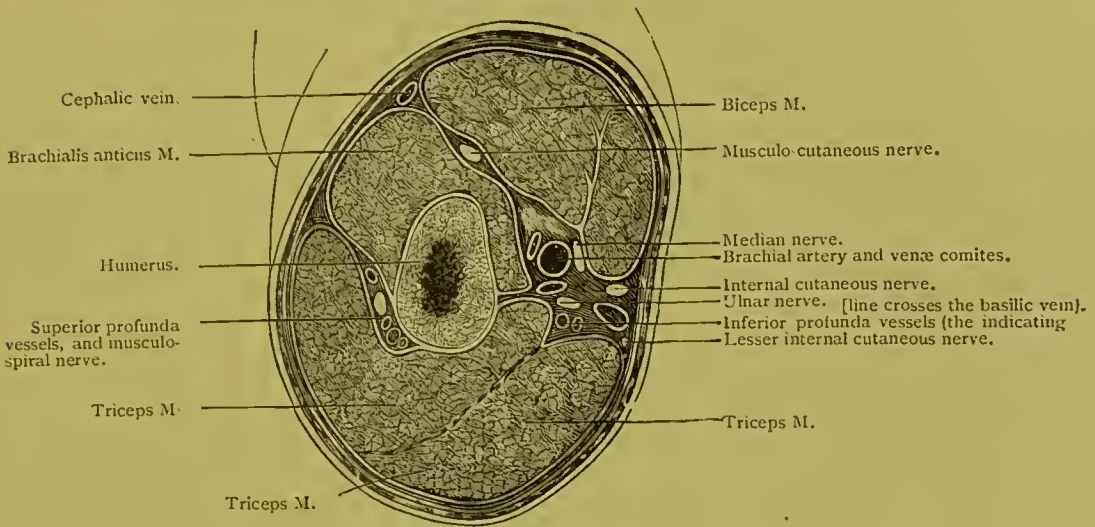


FIG. 51.—Transverse section through the middle of the right upper arm.

Surgical Anatomy.—The median nerve crosses the artery from without inwards, opposite the middle of the arm (Fig 50). The basilic vein in the lower half of its course lies superficial to the deep fascia.

Operation.—Make the incision (Fig. 46), two to three inches long, according to the thin or fat condition of the arm. Avoid the basilic vein. Seek the edge of the biceps muscle, and divide the deep fascia close to it. It is desirable, if possible, to avoid opening the sheath of the biceps, but the tissues should be divided towards that side to avoid injuring the arterial branches coming off from the opposite aspect of the vessel. Retract the biceps to the outer side, and draw the median nerve

aside. The sheath of vessel will then be exposed, the vessel may be isolated, and a ligature applied in the usual manner, excluding the venæ comites.

Below the middle of the arm the median nerve lies on the inner side, and the needle should therefore be passed from within outwards.

The frequent variation in the relations of this artery must be remembered. It often bifurcates high up, and one division may be superficial to the aponeurosis of the arm. The mobility of the neighbouring parts is considerable, and the sheath can readily be drawn aside by the retractor. If the incision be made too much internal the ulnar nerve will be exposed, and may be mistaken for the median.

LIGATURE OF THE BRACHIAL ARTERY IN THE UPPER THIRD OF THE ARM.

Surgical Anatomy.—The vessel lies on the inner aspect of the arm, covered by the integument and deep fascia, and overlapped by the basilic vein. The coraco-brachialis muscle and median nerve are on the outer side; the basilic vein, the ulnar and internal cutaneous nerves are on the inner side.

Guide.—Edge of the coraco-brachialis muscle.

Operation.—Abduct the arm. Make an incision three inches in length (Fig. 46) close to the border of the coraco-brachialis; the steps otherwise are similar to those in the middle third. The needle should be passed from the outer side, and great care taken that nothing save the vessel is included in the ligature.

Collateral Circulation (Fig. 52.)

BRACHIAL, above the origin of superior profunda.

Branches of circumflex (posterior) with $\left\{ \begin{array}{l} \textit{Ascending branches of superior} \\ \textit{profunda.} \end{array} \right.$

BRACHIAL, below the origin of inferior profunda.

Superior profunda (a) by termination with *Radial recurrent.*

$\left. \begin{array}{l} \textit{(b) by posterior ar-} \\ \textit{ticular branch} \end{array} \right\}$ with $\left\{ \begin{array}{l} \textit{Recurrent interossæous at back} \\ \textit{of joint.} \end{array} \right.$

Inferior profunda with $\left\{ \begin{array}{l} \textit{Anastomotica magna.} \\ \textit{Posterior ulnar recurrent.} \end{array} \right.$

LIGATURE OF THE AXILLARY ARTERY.

Indications.—Hæmorrhage from the brachial artery, or aneurism. Injury to the axillary artery itself, or aneurism. For aneurism of the subclavian, the distal operation.

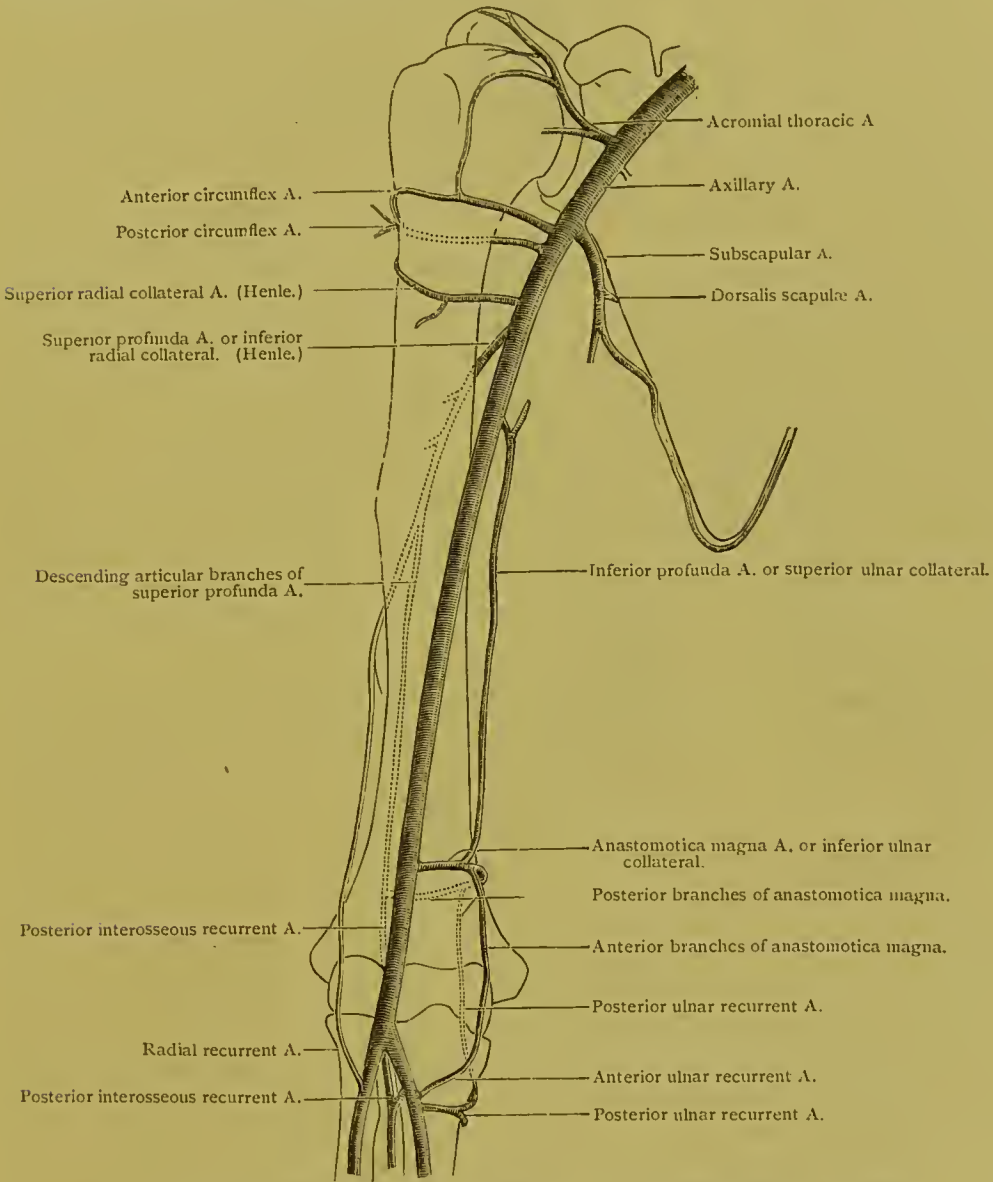


FIG. 52.—Anastomosing branches of axillary and brachial arteries.

Surgical Anatomy.—The axillary artery begins at the lower border of the first rib, opposite the mid-point of the clavicle, and terminates by

becoming the brachial artery at the lower border of the *teres major* muscle. When the arm lies by the side (Fig. 53), the artery is curved, the convexity being upwards and outwards. If the limb be placed at a right angle to the chest wall the vessel will be straight.

In its first stage below the clavicle, the axillary artery is very deeply

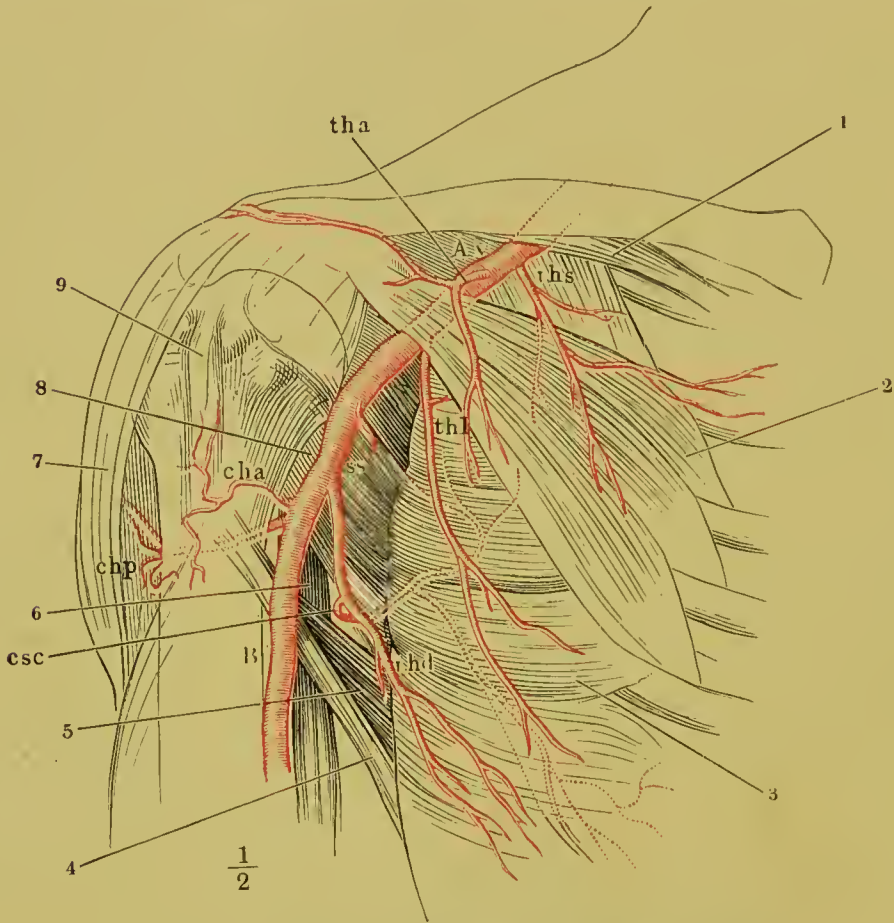


FIG. 53.—The axillary artery and its branches (Henle).

1. Subclavius M.
2. Pectoralis minor M.
3. Serratus magnus M.
4. Latissimus dorsi M.
5. *Teres major* M.
6. Long head of triceps M.
7. Deltoid M.
8. Subscapularis M.
9. Bicipital groove.

- Ax. Axillary artery.
 B. Brachial artery.
 ths. Superior thoracic A.
 tha. Acromial thoracic A.
 thl. Thoracica longa A.
 cha. Anterior circumflex A.
 chp. Posterior circumflex A.
 ss. Subscapular A.
 csc. Dorsalis scapulae A.
 thd. Thoracic branch of subscapular A.

placed on the first intercostal space and intercostal muscle. Ligature at this point, however, has been occasionally preferred to an operation upon the third stage of the subclavian artery. In the second stage the artery also lies very deep, and is almost inaccessible, being covered by the pectoralis major and pectoralis minor muscles, which would require to be divided in order to reach it. The artery may be ligatured in its third or axillary stage, where it has been from time to time injured by efforts to reduce old dislocations. This position has the disadvantage of a scanty collateral circulation (Fig. 52). It is here only covered by the skin, fasciæ, and the border of the pectoralis major muscle, and towards its termination is overlapped by the edge of the coraco-brachialis muscle. It rests on the subscapularis muscle above, and, lower down, upon the teres major and latissimus dorsi muscles. In front, and crossing to the outer side, lies the inner head of the median nerve. In this stage the median, and, for a short distance, the musculo-cutaneous, lie on the outer side. The ulnar and internal cutaneous nerves are on the inner side. Behind lie the musculo-spiral and circumflex nerves. The vessel is, therefore, near its termination, more or less closely surrounded by nerves, and covered by a plexus of veins, by lymphatics, and many lymphatic glands. The axillary vein is superficial and internal to the artery (Fig. 50).

Guide.—When the arm is extended from the side, a line drawn from the mid-point of the clavicle downwards and outwards along the posterior margin of the coraco-brachialis muscle will pretty accurately correspond to the course of the artery (Fig. 54).

OPERATION IN THE THIRD STAGE.

Abduct the arm. Make an incision through the skin and superficial fascia, three inches long (Fig. 54), from the middle of the axilla at the junction of its anterior and middle thirds, downwards along the posterior margin of coraco-brachialis muscle, which will serve as a guide to the artery. Depress the posterior margin of the wound, and retract the coraco-brachialis muscle; then draw the median nerve outwards, and the vein and artery will be found behind. The vein overlaps the artery from the inner side, and must be drawn inwards in order to expose it. Pass the needle close to the vessel from within outwards, taking every

precaution to avoid including any of the surrounding structures. The artery should be ligatured near its termination, to avoid too close a proximity to the subscapular and circumflex arteries.

OPERATION IN THE SECOND STAGE.

Except on account of wound it is inadvisable to attempt to ligate the artery in this situation.

OPERATION IN THE FIRST STAGE.

The artery may be tied in its first stage above the pectoralis minor, preferably before it gives off the acromial thoracic artery. Abduct the arm.

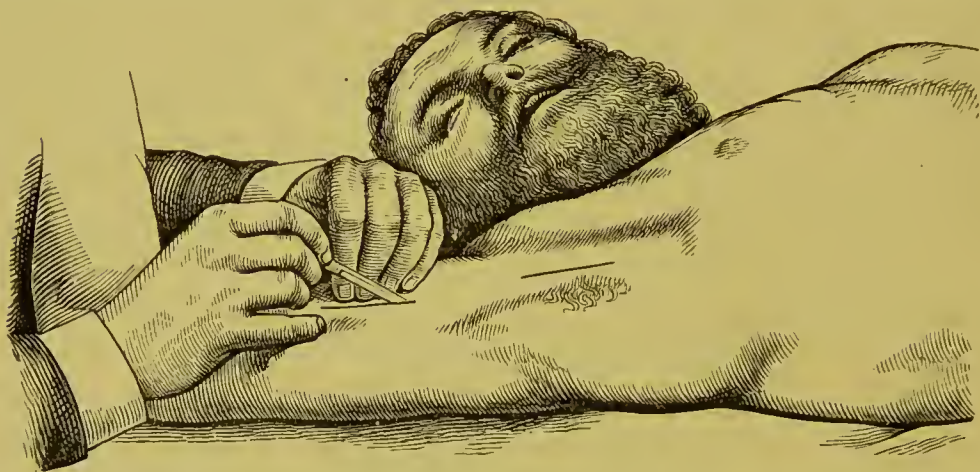

FIG. 54.—Position of the patient and of the line of incision for the ligature of the axillary artery in the third stage. The incision in the act of being made is that intended for ligating the upper part of the brachial artery. The fingers of the left hand are placed along the line of the wound so as to steady the skin during the first incision. The right hand is holding the scalpel in the position ordinarily adopted.

Make a curvilinear incision (Fig. 58), with its convexity downwards, three to four inches long, half an inch below the clavicle, and corresponding to its middle third. It should terminate externally close to the tip of the coracoid process, and internally about an inch from the sternum. Avoid the cephalic vein lying between the deltoid and pectoralis major muscles. This may be ensured by drawing the skin upwards over the clavicle and dividing it upon the bone. Divide the skin and subcutaneous tissues in the first incision, afterwards the pectoralis major throughout the extent

LIGATURE OF THE SUBCLAVIAN ARTERY.

Anatomical Relations.—The subclavian arteries form a curve in the neck, which, at its highest part, between the scaleni, often reaches the level of the sixth cervical vertebra. The height to which the artery rises in the neck, and the distance consequently to which it may project above the clavicle, vary considerably. In one case which came under my notice,

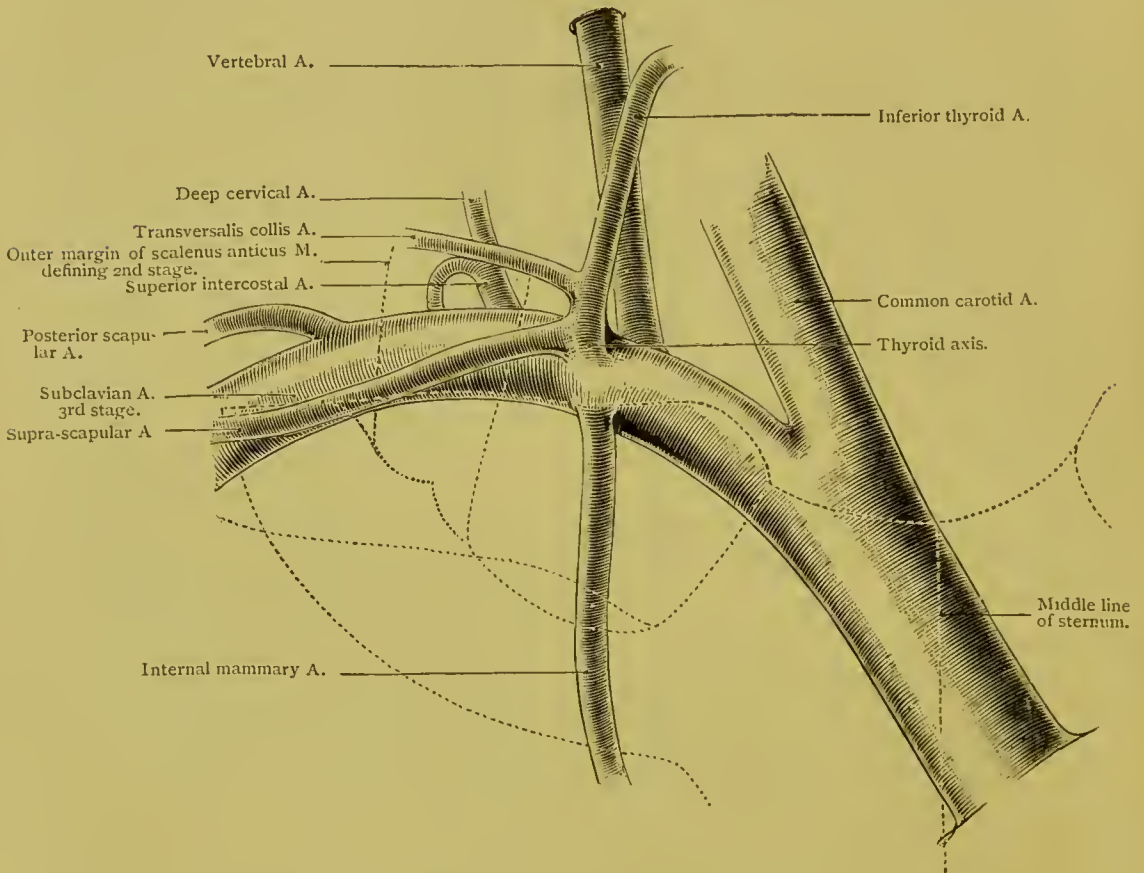


FIG. 55.—Diagram of the innominate artery, and right subclavian artery and its branches. The dotted lines indicate the relative positions of the sternum, clavicle, and first rib, with the attachment and outlines of the anterior scalenus muscle.

the subclavian artery was pushed forward by a supernumerary cervical rib on which it rested. Its pulsations were so strongly marked that an aneurism was for a time believed to exist. In persons with long thin necks

it is higher up and more superficial than in those with shorter necks. The first stage of the vessel differs on the two sides of the body. The second and third stages, in which alone the vessel may be ligatured with success, are the same on both (Figs. 55, 56).

The right subclavian is about three inches long, and is one inch shorter than the left. It arises from the innominate about the level of the upper border of the clavicle, frequently a little higher, and opposite the interval between the two portions of the sterno-mastoid muscle (Figs. 55, 57).

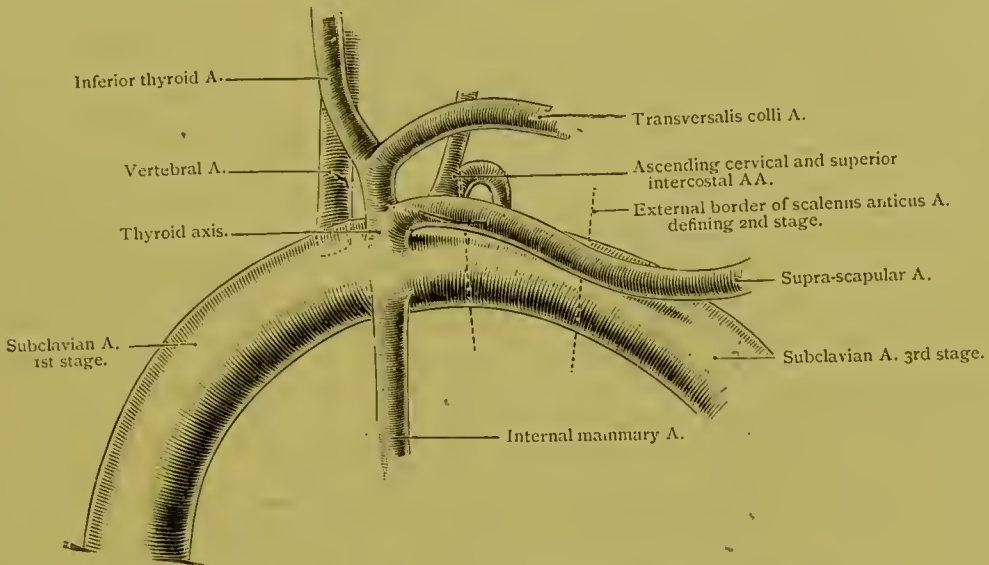


FIG. 56.—Diagram of the left subclavian artery and its branches.

The left subclavian arises from the arch of the aorta (Figs. 56, 59). It is more deeply situated in the thorax than the innominate. Both arteries terminate by becoming axillary at the lower border of the first rib.

The artery may be effectively compressed downwards and backwards against the upper surface of the first rib, at a point corresponding to half an inch inside the centre of the clavicle.

The artery has been tied in three places. It has been frequently ligatured in the third stage, rarely in the second, and very rarely in the first. The operation for ligature of the artery internal to the scalenus has been uniformly fatal. Secondary hæmorrhage occurred from the distal side in nearly every case. Ramsden, in 1809, first ligatured the vessel in its third portion for axillary aneurism.

LIGATURE OF THE SUBCLAVIAN ARTERY IN THE THIRD STAGE.

Indications.—A ligature has been applied at this point for axillary aneurism, innominate and aortic aneurisms (distal ligature), accidental wound, and occasionally as preliminary to disarticulation at the shoulder-joint,

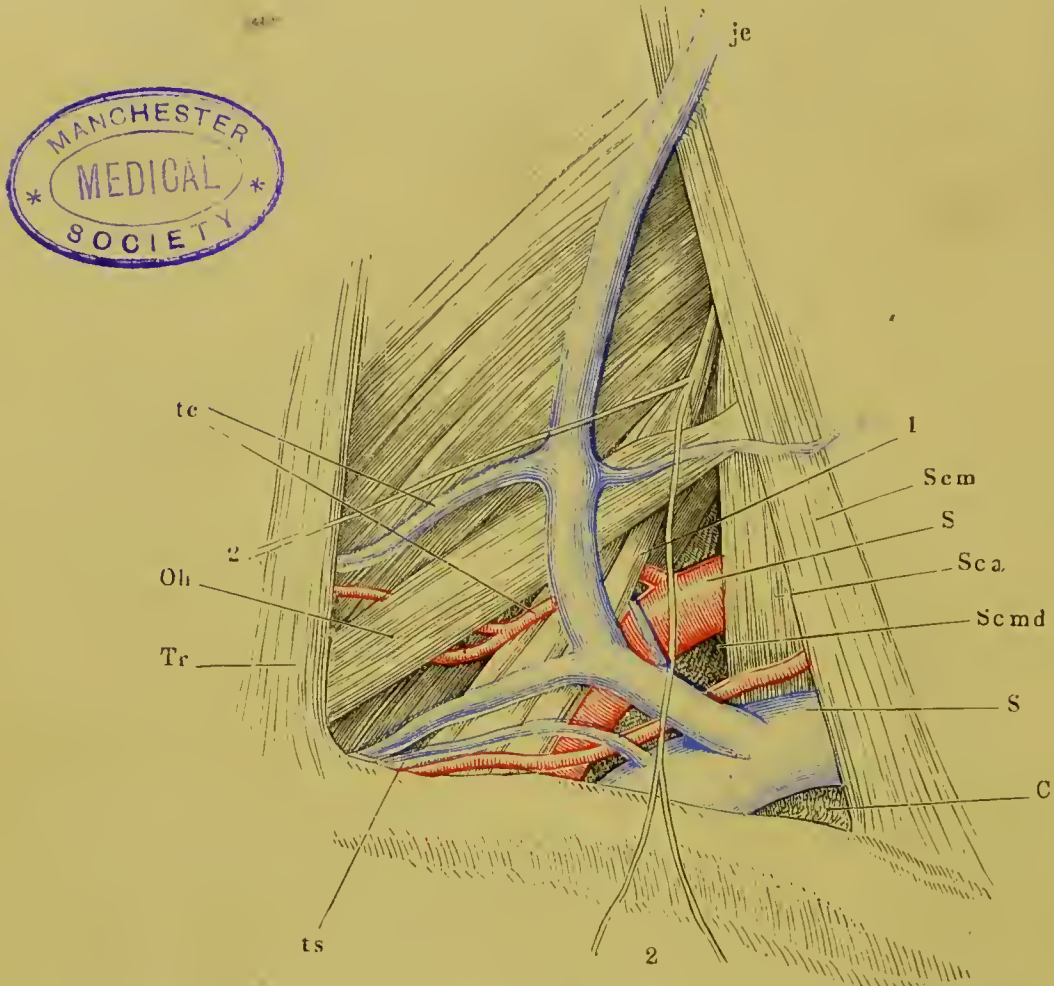


FIG. 57.—Relation of the parts contained in the supra-clavicular fossa (Henle).

- | | |
|--|--|
| Scm. External border of the sternomastoid M. | 1. Brachial plexus. |
| Sca. Scalenus anticus M. | 2, 2. Supra-clavicular nerves. |
| Scmd. Scalenus medius and posticus MM. | S. S. Subclavian artery and vein. |
| Oh. Omo-hyoid muscle. | tc. Transverse cervical artery and vein. |
| Tr. Anterior border of trapezius M. | ts. Transversalis humeri or supra-scapular artery, and vein. |
| C. First rib. | je. External jugular vein. |

or excision of the scapula. When performed for axillary aneurism, ligature of the subclavian has been frequently followed by suppuration of the sac.

Surgical Anatomy of the third portion.—This is the easiest and best situation for the application of a ligature. The artery passes downwards and outwards (Figs. 57, 59) from the outer margin of the scalenus anticus muscle to the lower or outer border of the first rib, on which, for the most part, it lies. It is about an inch to an inch and a half in length.

After dividing the superficial structures, a triangular space will be exposed bounded by the sterno-mastoid, omo-hyoid, and clavicle (Fig. 57). Within this the artery crosses obliquely from above downwards and outwards. Ascertain the position of the external jugular vein, usually near the posterior border of sterno-mastoid. The transverse cervical artery may cross the upper part of the wound, or perhaps not come into view at all (Fig. 59). The supra-scapular is usually concealed beneath the clavicle. The vessel, covered by the deep fascia, is situated in a deeper triangle bounded by the scalenus anticus on the inner side, the brachial plexus above and also behind the artery, and the subclavian vein rather in front and below. The lowest cord of the plexus formed by the last cervical and first dorsal nerves is in close contact with the posterior surface of the third stage of the vessel. The posterior scapular may arise as a separate branch from this portion of the artery (Fig. 55).

Guide.—The place where a ligature is applied in this stage of the artery corresponds to a point half an inch internal to the centre of the clavicle, or close to the outer border of the sterno-mastoid. The scalenus anticus lies behind the junction of the middle with the inner third of the clavicle. When the deeper structures are reached, we must take care to keep below the omo-hyoid muscle, and then to trace the outer border of the scalenus anticus to the tubercle on the first rib. The outer border of this muscle is the best guide to the artery which lies just external to and behind it, upon the upper surface of the rib.

Operation.—Depress the shoulder, extend the head and neck, and turn the face the opposite side. Make an incision through the skin and platysma, three to four inches long, parallel to, and half an inch above, the clavicle, corresponding to its middle third (Fig. 58). This may be conveniently and safely done by drawing the skin downwards upon the surface of the clavicle, and cutting right down to the bone. In this way, therefore, divide upon the bone the skin, platysma, and the two layers of superficial

fascia. All injury is thus avoided to the external jugular vein, as it perforates the deep fascia about three-quarters of an inch above the clavicle, and it should afterwards be drawn outwards rather than inwards, on account of the plexus formed by the transversalis colli and supra-scapular veins entering it from the outer side. If the external jugular vein, however, interfere with the ready exposure of the artery, it must be secured by a double ligature and divided (Fig. 57). A short superficial

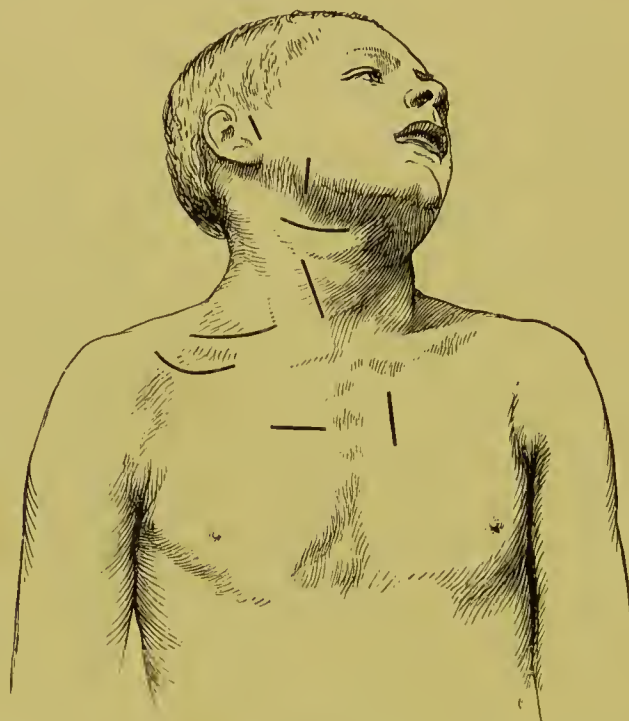

FIG. 58.—Indicates the positions of the lines of incision made for the purpose of ligating the temporal, facial, lingual, carotid (above omo-hyoid), subclavian, axillary (first stage or below clavicle), and internal mammary arteries.

incision upwards along the outer margin of the sterno-mastoid from the internal extremity of the first incision will give much additional space (Fig. 58). Cut carefully the deep cervical fascia close to the clavicle, and tease through the remaining cellular tissue with the finger-nail or a director. Avoid the supra-scapular artery and vein, which frequently lie nearly in front of the subclavian artery, passing horizontally outwards either immediately behind or just above the clavicle (Fig. 55). Sometimes the

external jugular, supra-scapular, and transverse cervical veins form a plexus immediately over the artery, a circumstance which considerably increases

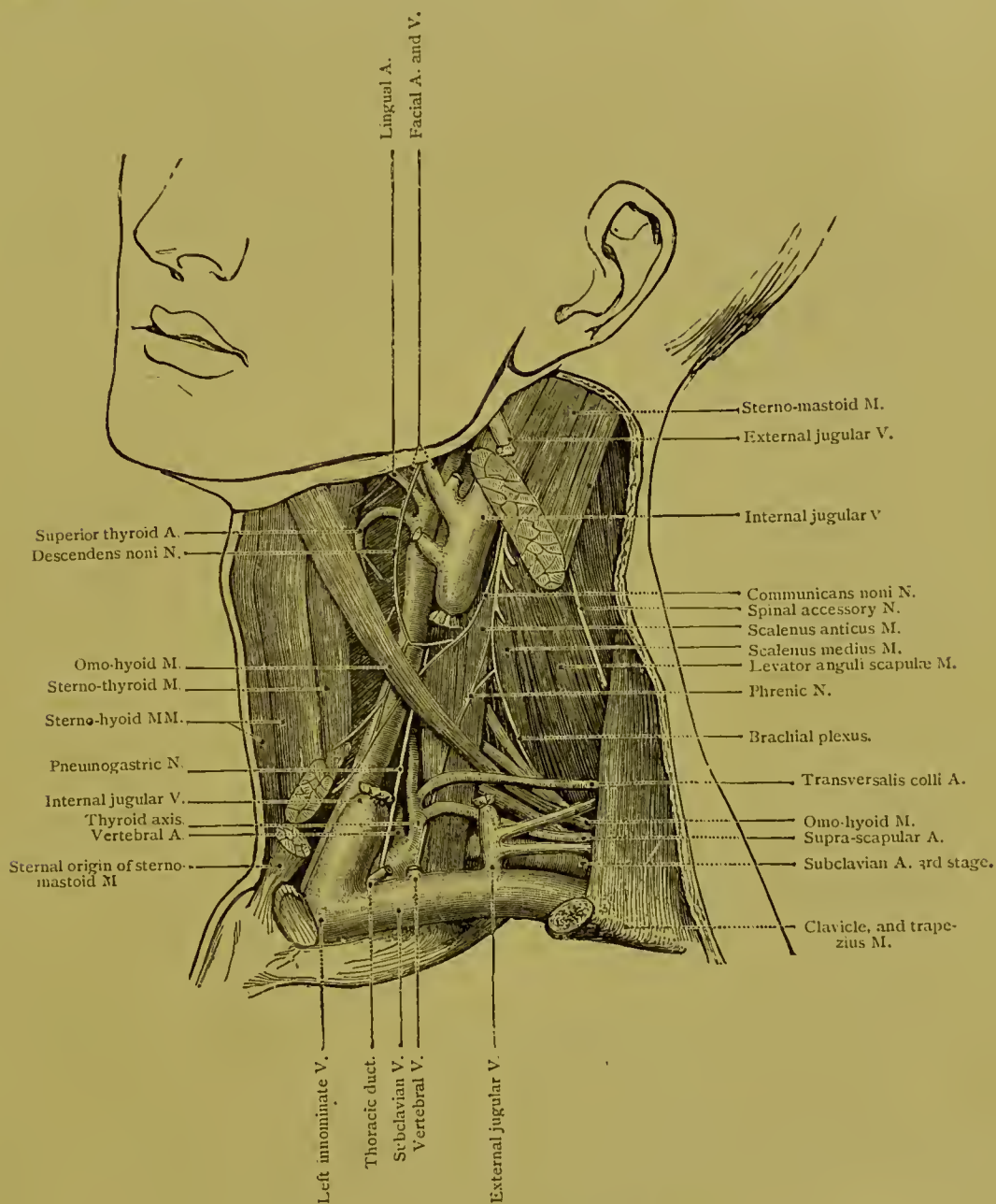


FIG. 59.—Surgical anatomy of the neck.

the difficulty of the operation. The posterior belly of the omo-hyoid may be exposed in the upper part of the wound. Trace the tense border of the

anterior scalene muscle down to the tubercle on the rib. It is well to keep the left forefinger on this till the artery shall be discovered lying just external and a little behind. After opening the sheath with some blunt instrument, pass the needle close behind the vessel from below upwards. There is a great liability to include the lowest cord of the brachial plexus, or even to mistake it for the artery when operating upon the dead subject, an accident which has taken place on the living. The artery is flattened and ribbon-like, the cord of the plexus is rounded and tense. To avoid including it, the needle may be passed from above downwards. In this way, however, both the subclavian vein and the pleura will be in considerable danger, but they may be pushed aside.

LIGATURE OF THE SECOND STAGE OF THE SUBCLAVIAN ARTERY BETWEEN THE SCALENI MUSCLES.

Anatomical Relations.—The artery lies between the anterior and middle scalene muscles. The anterior scalenus, upon which the phrenic nerve passes obliquely downwards and inwards, separates the artery from the subclavian vein. Behind and below is the apex of the pleura. The cords of the brachial plexus are above (Fig. 59).

Guide.—Scalenus anticus.

Operation.—This part of the artery may be reached in the wound made for ligature of the third stage after dividing the outer part of the scalenus, or by making an incision similar to, but more internal than, that for third portion. Divide the skin, platysma, and cervical fasciæ as before, also the outer part of the sterno-mastoid, and the outer portion of the scalenus muscle near its insertion. Carefully avoid injuring the phrenic nerve, which here lies near the inner border of the muscle. The transverse cervical and supra-scapular arteries are sometimes in the way. It must be remembered that the superior intercostal very often arises from this stage of the artery (Fig. 55). The operation is usually performed as a modification of that for the third stage. With care the scalenus may be partially or even completely divided without injury to the phrenic nerve or the internal jugular vein. The pleura may readily be injured while passing the needle, which should, if practicable, be directed from below upwards. Inflammation of the pleura and lungs has frequently been the fatal consequence of ligature of the sub-

clavian artery in this situation. The operation is not to be recommended. It is very fatal from secondary hæmorrhage, as the vessel must be tied in close proximity to many branches (Figs. 55 and 56). Dupuytren, who first recommended the operation, is said to have performed it several times.

LIGATURE OF THE FIRST STAGE OF THE ARTERY INTERNAL TO THE SCALENI MUSCLES.

Surgical Anatomy.—On the right side (Figs. 55, 65) the vessel arises from the innominate usually just behind the sterno-clavicular joint, and passes obliquely upwards and outwards to the inner border of the scalenus. Several large arterial branches are given off at short intervals (Fig. 55). It is covered by the sterno-mastoid, sterno-hyoid, and sterno-thyroid muscles, the pleura lies behind and beneath. The artery is crossed anteriorly by the pneumogastric, phrenic and cardiac nerves, internal jugular, and vertebral veins, while the recurrent laryngeal nerve arches round its inferior border (Fig. 65.)

The artery on the left side (Figs. 56, 59) is longer and more deeply placed, as it takes its origin from the aorta. The thoracic duct arches over it from behind, and then crosses in front of the subclavian artery to pass downwards behind the internal jugular vein to empty into the subclavian vein. The innominate vein is in anterior relation to its lower part. The other relations are as on the right side (Fig. 59.)

Operation.—On the right side the ligature of the first stage of the vessel is very difficult, and unadvisable. It has been but rarely performed, and never successfully. The operation is similar to that for tying the arteria innominata. On the left side the ligature of the vessel in this situation is nearly impracticable.

Collateral Circulation.—Subclavian Artery in its Third Stage or outer portion of Second (Fig. 60).

Suprascapular	with	{	Subscapular (especially the dorsalis scapulæ branch.
" by supra-acromial and articular branches		}	Acromio-thoracic and circumflex of axillary.
Posterior scapular	with		Subscapular.
Aortic intercostals		}	Thoracic branches of axillary and subscapular arteries, and several small unnamed branches.
Anterior intercostals and perforating branches of internal mammary	with		

LIGATURE OF THE VERTEBRAL ARTERY.

Indications.—This vessel has been tied for injury, for the attempted cure or relief by the distal operation of aortic, innominate, and also subclavian aneurisms, and in the treatment of epilepsy. The operation was first performed by Smyth of New Orleans in 1864.

Surgical Anatomy.—The artery (Figs. 61, 62, 64) arises about one-third of an inch internal to the inner border of the scalenus anticus muscle from the upper and back part of the first stage of the subclavian artery, of which it is the first and most important branch. The size of the vessel is often different on each of the two sides of the neck, that on the left side being generally the larger. Passing upwards and slightly backwards, the vessel enters the foramen in the transverse process of the sixth cervical vertebra. Occasionally it enters the fifth, more rarely the seventh, transverse process. It ascends through the foramina, passing outwards over the upper border of the axis to enter the foramen in the atlas. Then it winds in a deep groove on the surface of the posterior arch of this bone, pierces the occipito-atloid ligament and dura mater, and enters the skull through the foramen magnum. Here it joins its fellow from the opposite side beneath the pons in order to constitute the basilar artery by which through the circle of Willis the carotids and vertebrales communicate. Only before entering the foramina is it accessible for purposes of ligature. This portion of the vessel is about an inch and a quarter long. It ascends in the interval between the longus colli and scalenus anticus muscles, the vertebral vein lying immediately in front (Fig. 61). The artery is very deeply placed behind its own vein, the internal jugular vein, the vagus nerve, and the inferior thyroid artery which crosses its course and separates it from the common carotid artery. A plexus of the sympathetic from the inferior cervical ganglion accompanies it, and on the left side the thoracic duct comes into anterior relation with it.

Operation.—The vessel may be best reached by an incision along the posterior border of the sterno-mastoid muscle, about three inches long in the adult neck, and terminating below at the clavicle. After dividing the deep fascia the muscle should be drawn inwards. If additional room be

required, a horizontal cut from the lower end of the first incision can be made inwards along the upper border of the clavicle, and a portion of the clavicular

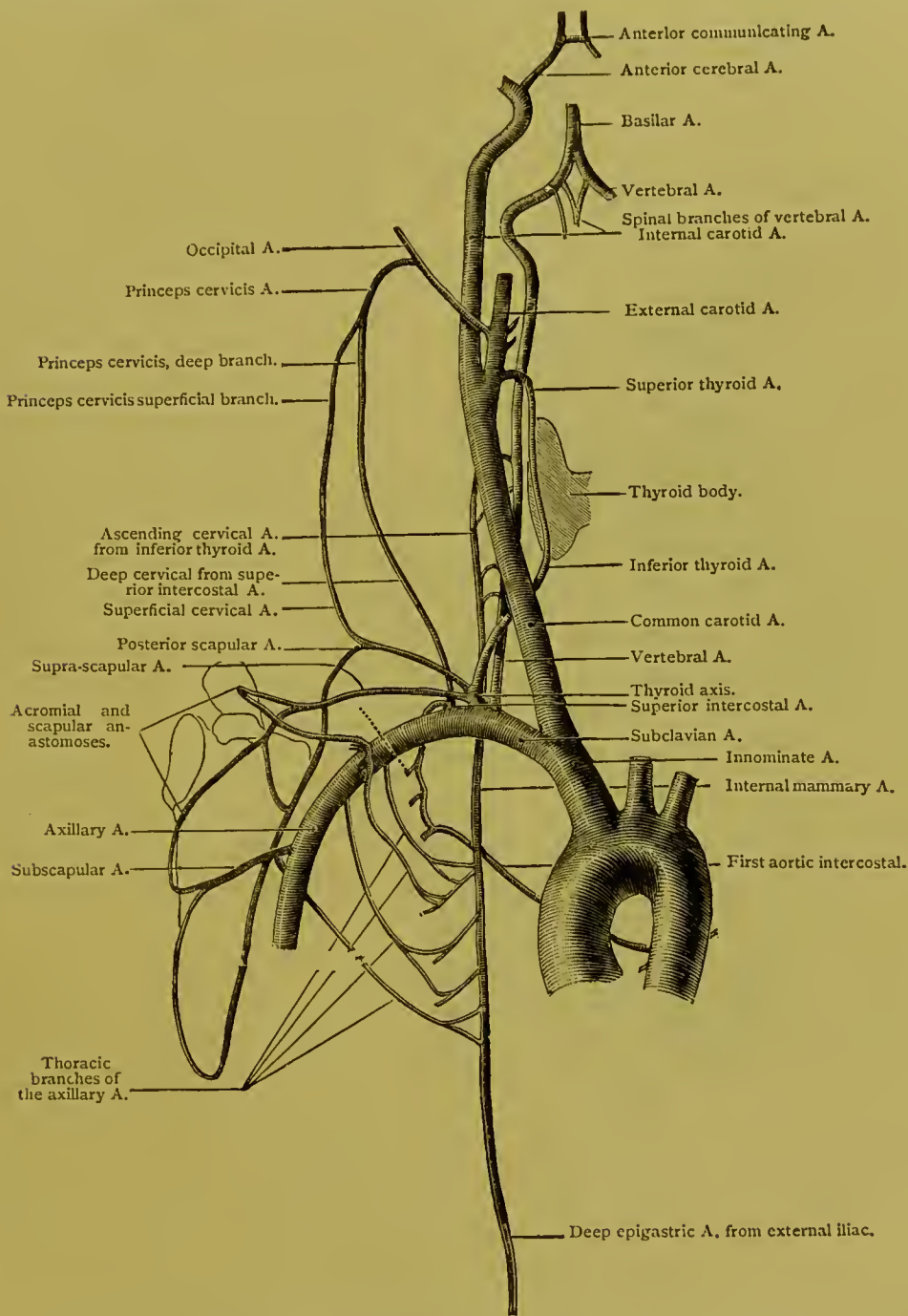


FIG. 60.—Diagram of the anastomoses of the subclavian and carotid arteries.

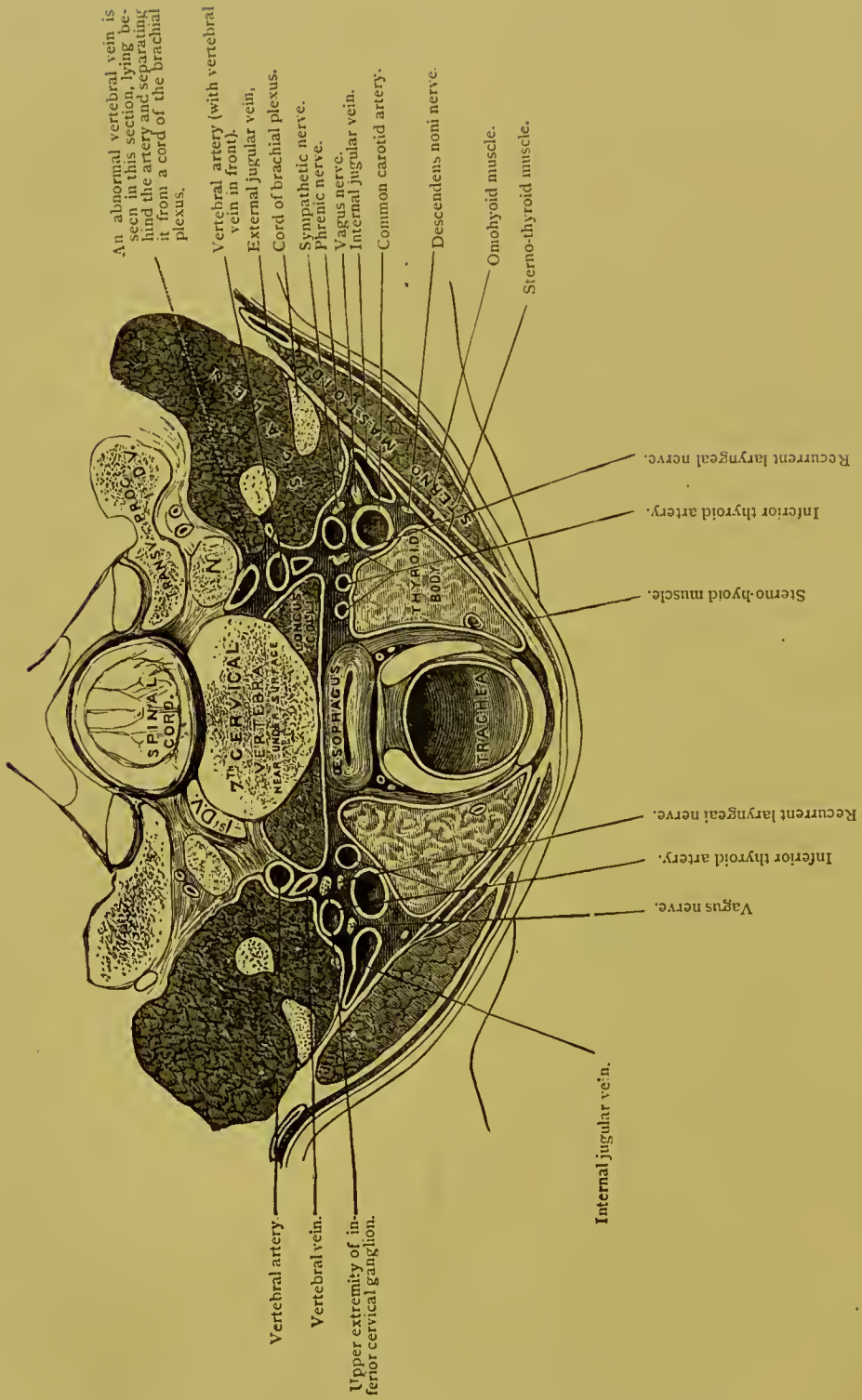


FIG. 61.—Transverse section through the neck at the level of the seventh cervical vertebra.

attachment of the sterno-mastoid divided. The loose cellular tissue lying inside the scalenus anticus muscle must now be sought for, and on fully retracting the sterno-mastoid, together with the carotid sheath and internal jugular vein which is generally visible, the space between the scalenus and longus colli muscles, in which the artery lies, will become exposed. Separating the tissues with the end of the director suffices to isolate the vessel, which can then be secured by passing the needle from without inwards. The vein lying directly in front of the artery must be avoided. The inferior thyroid and ascending cervical arteries have been sometimes mistaken for the vertebral. Immediate contraction of the corresponding pupil, due to interference with the dilating fibres of the cervical sympathetic, is of very constant occurrence, and may be regarded as a pretty certain indication that the vessel has been secured. Two small nerves from the inferior cervical ganglion, at first a little separated from the artery, are afterwards very closely applied to it. When these are included in the loop of the ligature the contraction of the pupil will continue for a considerable time. A temporary contraction will occur even when the nerves are excluded, because of the almost unavoidable irritation to which they are subjected during the steps of the operation.

The phrenic nerve lying on the scalenus need not be exposed. It is sufficiently external to be out of danger. The transverse, cervical and inferior thyroid arteries sometimes come in the way. If the posterior belly of the omo-hyoid be exposed, it may be drawn upwards and outwards, or divided if it interfere with the further progress of the operation.

LIGATURE OF THE INFERIOR THYROID ARTERY.

Indications.—This vessel has been ligated with a view to arrest the growth of bronchocele. It is also of necessity ligated during the removal of the thyroid gland.

Surgical Anatomy.—This artery is the largest branch of the thyroid axis, given off from the first stage of the subclavian (Figs. 62, 63, 64, 66). It first ascends a little and then passes inwards behind the internal jugular vein, pneumogastric nerve, and carotid artery. The sympathetic trunk overlies the vessel, the middle cervical ganglion usually resting upon it. Near its entrance into the gland it is in close relation with the recurrent laryngeal

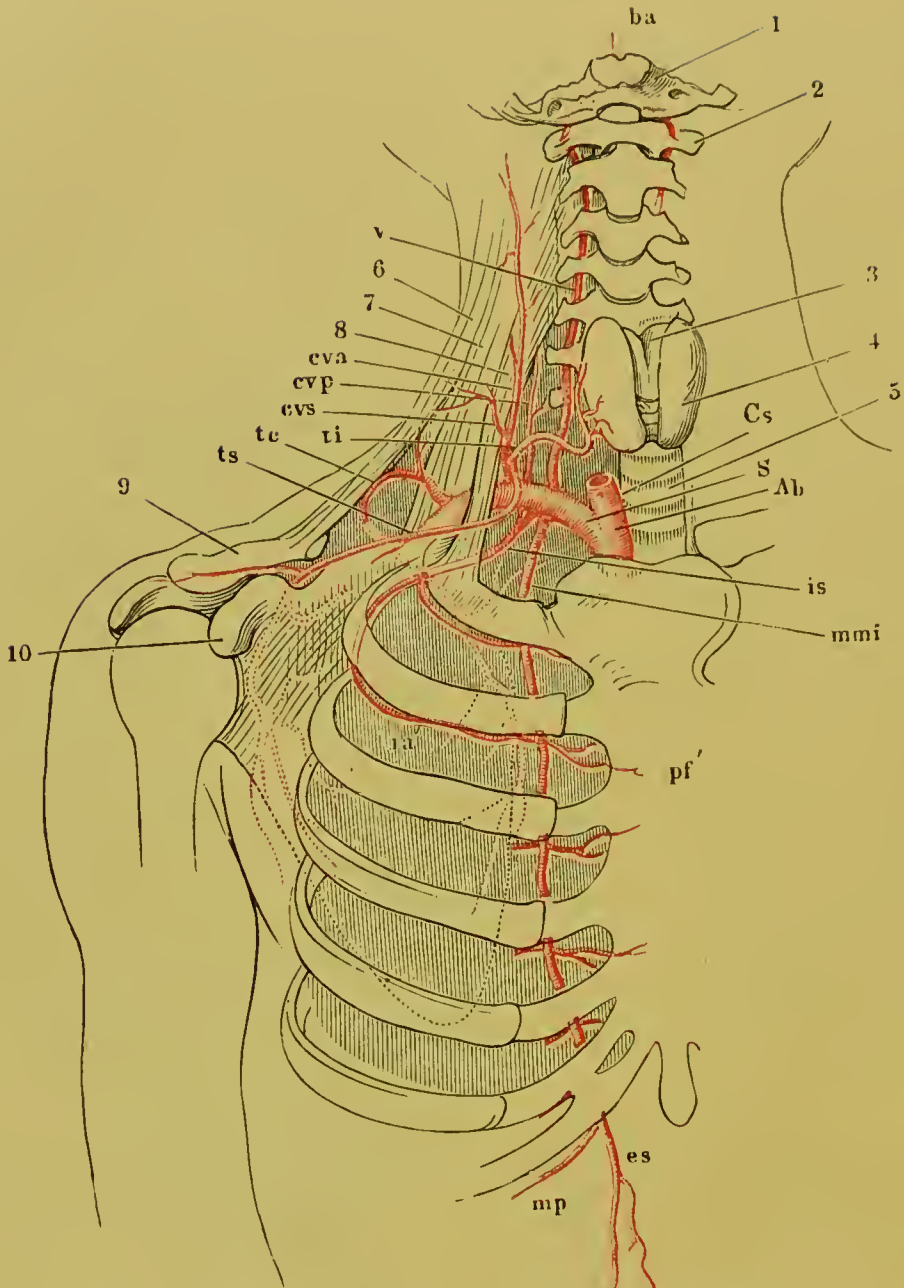


FIG. 62.—The right subclavian artery and its branches (after Henle, §).

- 1. Occipital bone.
- 2. Atlas.
- 3. Thyroid cartilage.
- 4. Thyroid gland.
- 5. Trachea.
- 6. Trapezius.
- 7. Scalenus medius and posticus.
- 8. Scalenus anticus.
- 9. Clavicle.
- 10. Coracoid process.

- Ab. Arteria innominata.
- Cs. Common carotid A.
- S. Subclavian A.
- ba. Basilar A.
- mmi. Internal mammary A.
- v. The vertebral artery is seen coming off from the subclavian opposite the origin of the internal mammary A.
- pf. Perforating branches.

- is. Superior intercostal A.
- es. Superior epigastric A.
- mp. Musculo-phrenic A.
- ti. Inferior thyroid A.
- cva. Cervicalis ascendens A.
- cvp. Deep cervical A.
- cvs. Superficial cervical A.
- tc. Transversalis colli A.
- ts. Transversalis humeri or supra-scapular A.

nerve (Fig. 63), which often passes between its terminal branches. On the left side it lies upon the œsophagus. The thoracic duct, at first posterior, afterwards arches over in front of the artery to enter the left subclavian vein.

In the operation of œsophagotomy the left inferior thyroid artery may be accidentally divided.

Guide.—The best indication, perhaps, is the body of the fifth cervical vertebra, opposite to which the artery enters the thyroid gland.

Operation.—Make an incision three inches in length along the anterior border of the sterno-mastoid, as if for ligature of the common carotid

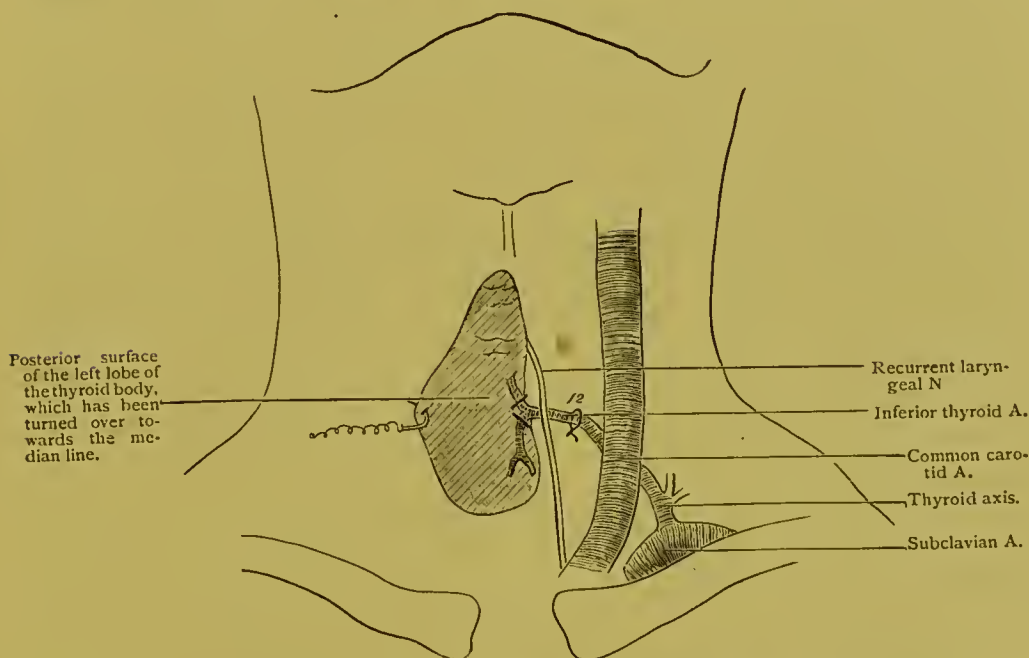


FIG. 63 —Plan of the relations of the inferior thyroid artery, carotid artery, recurrent laryngeal nerve, and thyroid gland (after Kocher).

artery below the omo-hyoid. When the carotid sheath is exposed draw it outwards. The artery will be found crossing obliquely inwards opposite the point mentioned. After fully exposing the vessel, apply the ligature some distance from the thyroid body, as near to the carotid as possible, in order to avoid injury to the recurrent laryngeal nerve, which either crosses over the main trunk of the artery or ascends amidst its branches. The vessel passes behind the thyroid gland before dividing into branches to pierce the deep surface (Fig. 63).

LIGATURE OF THE INTERNAL MAMMARY ARTERY.

Indications.—The artery may require ligature on account of injury.

Surgical Anatomy.—This vessel arises from the lower and anterior part of the first stage of the subclavian (Figs. 62, 64), close to the inner margin of the scalenus anticus, at a point corresponding to the interval between the heads of the sterno-mastoid muscle. It runs directly downwards, and at first slightly inwards, between the cartilages of the upper six ribs and the pleura, about half an inch from the border of the sternum. Except in the first and second intercostal spaces the triangularis sterni muscle separates it from the pleura. The phrenic nerve crosses over it from without inwards close to its origin. Opposite the sixth interspace the vessel usually divides into the superior epigastric and musculo-phrenic arteries (Fig. 62).

Operation.—The vessel may be ligated in the second, third, or fourth intercostal spaces. Lower down it becomes much smaller. Make a transverse incision (Fig. 58), commencing upon the edge of the sternum and running outwards for two inches, parallel to and midway between the costal cartilages. Divide the skin, the fibres of the pectoralis major, the internal intercostal muscle, and any fibres of the external intercostal that may be present. Carefully avoid injuring the pleura, upon which, in the first and second spaces, the artery lies accompanied by two veins, while lower down it rests upon the triangularis sterni muscle. The vessel may also be exposed by a vertical incision from the middle of one rib to the next, made half an inch external to the margin of the sternum.

Another plan employed to expose it has been by excising a portion of one of the costal cartilages. An incision for this purpose should be made directly upon the cartilage from the margin of the sternum outwards for two inches. The perichondrium must now be carefully separated with an elevator to avoid injuring the pleura. When this is done the costal cartilage can be readily divided with cutting forceps, or the cartilage having been prized forwards with the elevator may be cut through with a scalpel.

LIGATURE OF THE INNOMINATE ARTERY.

Indications.—Aneurisms of the subclavian and carotid arteries. The operation has been seldom performed—about sixteen times in all.

Hitherto, with one exception, that of Smyth of New Orleans in 1864, it has invariably proved fatal, although in some instances life has been prolonged for a considerable period. In Thompson's case the patient survived forty-two days. In Smyth's case secondary hæmorrhage repeatedly occurred, and the carotid and vertebral arteries were successively tied. It is doubtful whether the operation be a justifiable one. Secondary hæmorrhage has usually been the fatal sequela of surgical interference. Valentine Mott first performed the operation in 1818 for subclavian aneurism.

Anatomical relations.—The *arteria innominata* (Figs. 60, 62, 64, 65) arises from the first part of the transverse portion of the aortic arch just behind the middle of the sternum, at a level varying from an inch to an inch and a half below the sternal notch. It usually bifurcates into the subclavian and carotid arteries near the upper margin of the clavicle, and behind the interval between the sternal and clavicular origins of the sterno-mastoid muscle. The length of the vessel varies from one to two inches. In front of it lie the sternum, the sterno-hyoid and sterno-thyroid muscles. The left innominate vein crosses it near its origin. The vessel on its left side is in relation with the left carotid artery and inferior thyroid vein, on the right with the right innominate vein and with the pneumogastric nerve and pleura. Immediately behind it is the trachea. The two *venæ innominatæ* unite about half an inch below the bifurcation of the artery to form the *vena cava*, which descends to the right of the *arteria innominata* on a plane somewhat anterior to it. Important parts surround this artery on all sides, and its deeply placed position, behind the sternum, renders it difficult and hazardous to reach.

Direction.—The vessel ascends behind the manubrium sterni obliquely upwards and to the right side from its origin at the arch of the aorta to the bifurcation opposite the sterno-clavicular articulation, above which, however, it frequently ascends for some little distance before terminating. In other instances the bifurcation will be quite behind the sternum.

Operation.—The patient's shoulders should be well supported, the right arm drawn downwards, and the head inclined backwards and to the left side. Make an incision, three inches in length, along the upper border of the clavicle, beginning at the median line, and a second, of the same length,

upwards, along the inner margin of the sterno-mastoid. Divide the sternal and part of the clavicular origins of the muscle on a director passed close underneath them, also the sterno-hyoid and sterno-thyroid muscles in a similar fashion. The commencement of the carotid artery will first be met with and forms a guide to the vessel. The carotid artery being discovered will now have to be traced downwards to its origin, and the position of

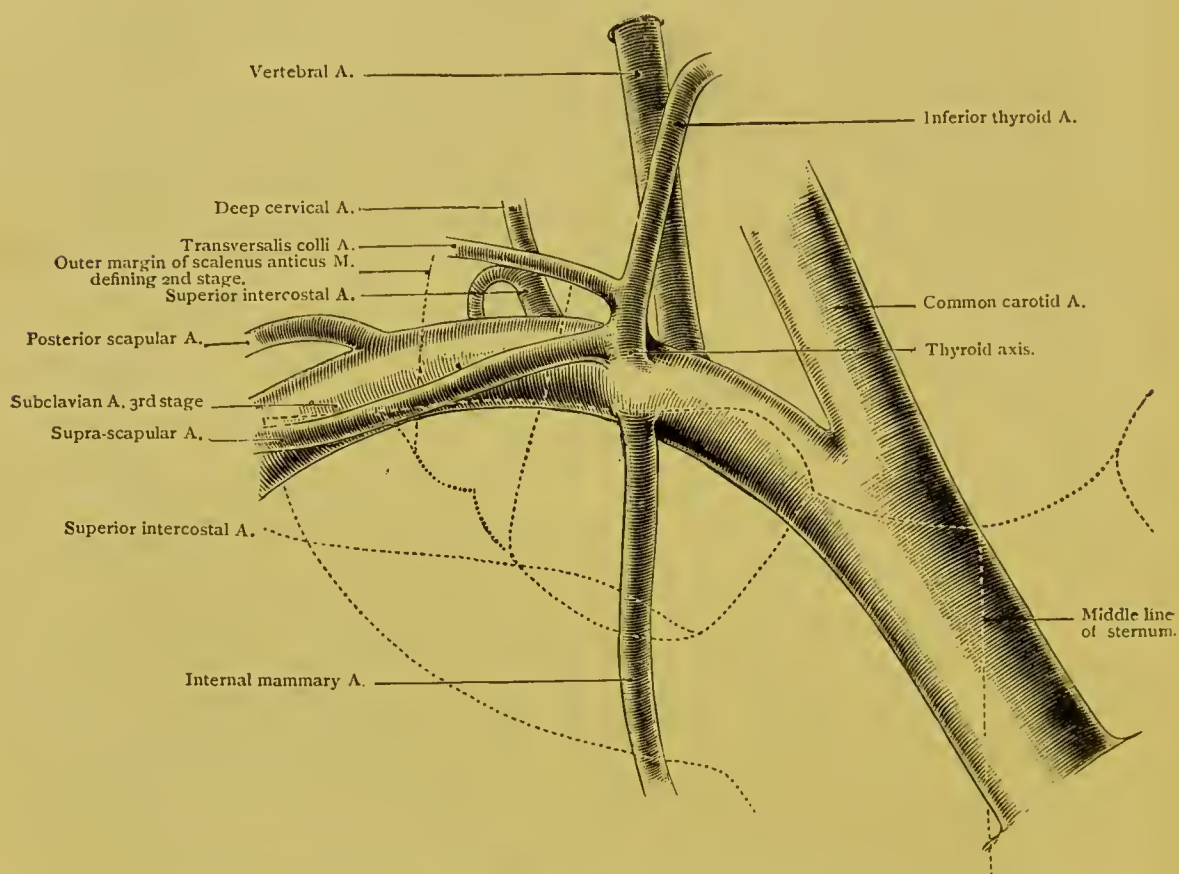


FIG. 64.—Diagram of the innominate, right subclavian artery and its branches.

the parent trunk ascertained. In order fully to expose the artery it will be necessary to tear through a dense fascia covering it, carefully to separate the thyroid plexus of veins and left innominate vein, and then to isolate the vessel behind the sternum. Apply the ligature, if possible, near to the middle of the trunk. The right pleural sac, in which the artery is partly imbedded, may be readily injured when passing the aneurism needle. The direction given to the needle should be from below and external upwards and inwards,

keeping closely to the artery to avoid the pleura, pneumogastric and cardiac nerves, all lying to the outer side.

It proved necessary in one case to remove the inner part of the clavicle. The removal of the manubrium sterni, or a portion of it, has also been suggested, in order to give the necessary room.

Another plan is worthy of mention, for, although I do not know that it has been practised on the living subject, it is of easy accomplishment on the dead. It consists in taking advantage of the close relationship of the innominate with the trachea, the possibility of separating the sternal muscles in the median line without dividing them, and the absence of any important source of bleeding in this situation, except in case of injury to the great veins at the base of the neck. These may be pushed aside, and in the absence of any obstruction to the respiration will probably not be overfilled. The operation consists in making a vertical incision in the middle line immediately above the sternum, extending for three inches above the notch and dividing merely the skin and fasciæ. The interstice between the sterno-hyoid and sterno-thyroid muscles having been found, these muscles are separated and held aside, and then with the use of some blunt instrument the first part of the carotid and the innominate itself can be exposed without any considerable difficulty, or risk of injury to the veins. The aneurism needle should be passed with equal care in the manner already mentioned.

Collateral Circulation (Fig. 60).

	CARDIAC SIDE.		DISTAL SIDE.	
Trunk.	{	<i>First aortic intercostal</i>	<i>with</i>	<i>Superior intercostal of subclavian.</i>
		<i>Upper aortic intercostals</i>	<i>with</i>	{ <i>Thoracic branches of axillary, and intercostals of internal mammary.</i>
		<i>Phrenic</i>	<i>with</i>	{ <i>Musculo-phrenic of internal mam- mary.</i>
		<i>Deep epigastric</i>	<i>with</i>	{ <i>Superior epigastric of internal mammary.</i>
Head.	{	<i>Free communication of vertebrals and internal carotids of opposite sides inside the skull. Communication of branches of opposite external carotids in middle line of the face and neck.</i>		

LIGATURE OF THE COMMON CAROTID ARTERY.

Indications.—Aneurism of the external and internal carotids or their branches. Aneurismal varix. Intra-orbital aneurism. Repeated or profuse hæmorrhage from any of these vessels, either as a result of wound of the neck, or of ulceration due to abscess in the upper part of the neck or in the tonsil. Ulceration of the tongue and wounds in the mouth have also necessitated the operation. The artery has been ligatured on the distal side for the cure of aneurism near its origin, on the principle first proposed by Brasdor in 1790, or in accordance with the increased scope of the method recommended by Wardröp in 1822 ; a ligature may be placed on either the carotid or subclavian or both, for the relief of aneurism involving the innominate artery or the aortic arch. Desault approved the principle, but Deschamps, his contemporary, first performed the operation in France. The results of the distal operation have hitherto proved unfavourable. Ligature of the carotid artery alone appears to be less effective in innominate aneurism than ligature of the subclavian in its third stage. It is probably best to ligature both arteries in succession at an interval of some weeks. This operation has been performed about a dozen times. The larger number survived but a short period. In two cases benefit is stated to have followed. C. Heath performed the operation in a case of supposed innominate aneurism, but really aortic. He tied simultaneously the right carotid and subclavian arteries: the patient survived four years. In cases operated on by Barwell and others patients have survived for shorter periods. It may also be necessary to secure the carotid artery during operations for removal of tumours in the neck. The first case on record was performed by Hebenstreit, who ligatured the common carotid artery successfully in consequence of injury to the external carotid during the removal of a scirrhus tumour from the neck. For punctured and other wounds of the face and neck, either gunshot or suicidal, ligature may be needful. For hæmorrhage following gunshot injuries of the upper and lower jaw, the artery has been frequently tied. The rate of mortality after ligature for gunshot injury is very

high. Aneurism by anastomosis in the orbit, and upon the head, and aneurism of the middle meningeal artery, have also been treated by deligation of the vessel. The same treatment has been adopted, a score

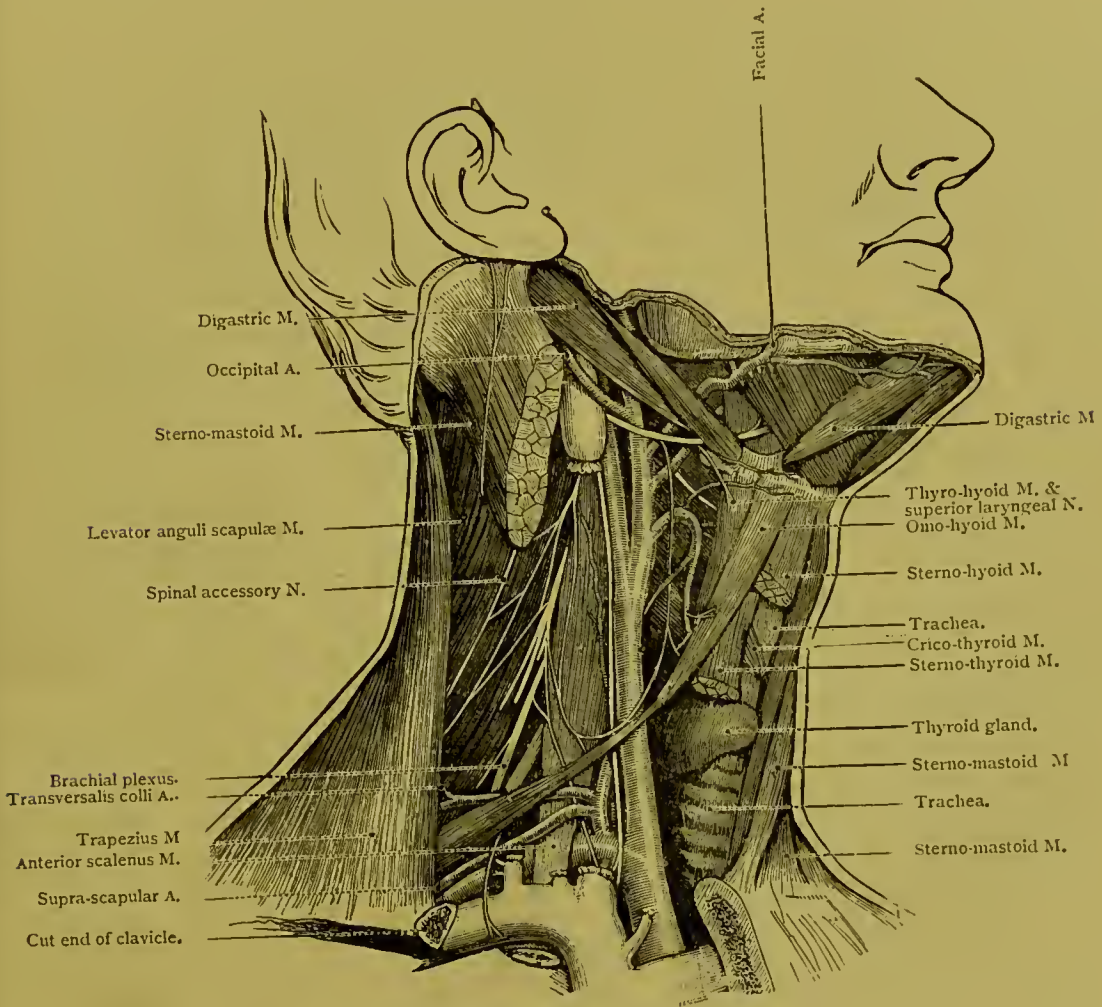


FIG. 65.—Surgical anatomy of the neck.

of times perhaps, for the cure of epilepsy, but although the mortality was not great the operation exerted but small influence upon the disease. The object for which it is undertaken is to diminish the supply of blood

to the dilated capillaries of the medulla. This will be as efficiently accomplished by the ligature of one or both vertebral arteries, as has been

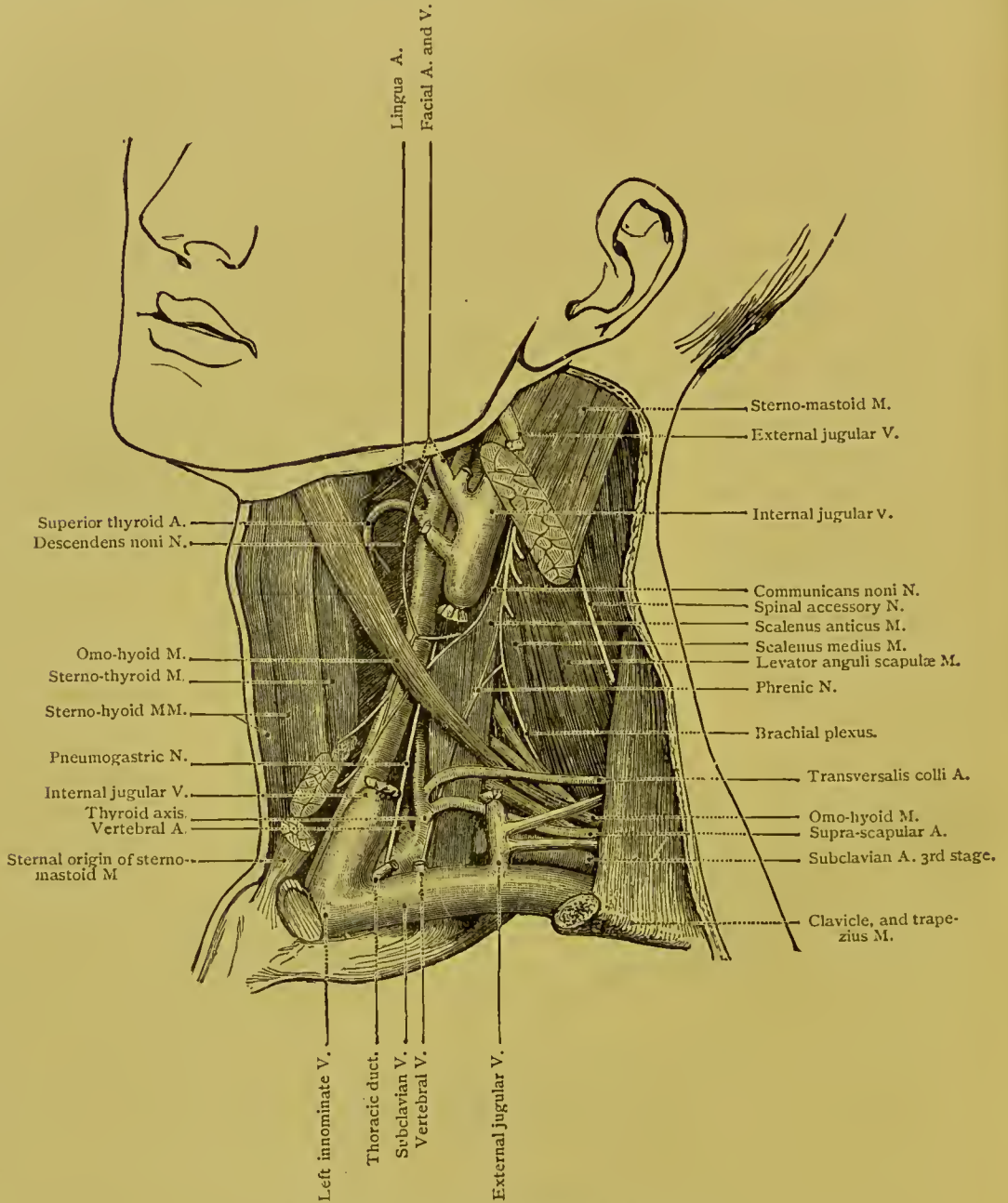


FIG. 66.—Surgical anatomy of the neck.

recently proposed. Sir Astley Cooper, in 1805, ligatured the carotid artery for aneurism for the first time.

Surgical Anatomy.—The artery arises on the right side from the innominate (Fig. 65), opposite the sterno-clavicular articulation, and on the left from the arch of the aorta. Passing upwards the vessels slightly diverge, and finally divide into the external and internal carotid arteries opposite the upper margin of the thyroid cartilage, a point corresponding to the third cervical vertebra, or about one inch below the angle of the jaw. The artery not infrequently bifurcates a little higher, sometimes as high as the hyoid bone, and occasionally even higher, less frequently lower. The common carotid is often crossed near its bifurcation by a communicating branch between the facial and the anterior jugular veins. Below this point, the superior thyroid vein and sterno-mastoid branch of the superior thyroid artery lie in front of the vessel. The superior thyroid vein may be double or form a plexus in front of the artery. The descendens noni usually lies upon the sheath, but is sometimes within it. The sterno-mastoid muscle passing upwards and outwards completely covers the lower portion of the artery. The artery emerges at its inner edge, about an inch and a half below the bifurcation (Fig. 70). The upper portion of the vessel is only covered by skin, platysma and cervical fasciæ.

The fascial sheath (Figs. 67 and 68), containing the carotid artery, internal jugular vein, and pneumogastric nerve, lies in front of the vertebræ, from which it is separated by the longus colli and rectus capitis anticus major muscles, the inferior thyroid artery, recurrent nerve and some loose areolar tissue. The sympathetic is also behind, the larynx and trachea are internal. The thyroid gland often overlaps the artery, and in cases of goitre may displace it to the outer or inner side, usually the former, or even envelop it completely. The pneumogastric nerve is placed between the artery and the vein, and posterior to both. The jugular vein is external, and generally separated from the artery by a septum in the sheath. It overlaps the vessel when full, and more completely on the left than the right side. On the right side, below the omo-hyoid muscle, the vein is separated from the artery.

The anterior belly of the omo-hyoid muscle crosses the sheath of the vessel obliquely on a level with the cricoid cartilage, and serves to divide the artery into a deep and superficial portion. The point at which this

muscle crosses the artery varies from one and a half to two and a quarter inches below the bifurcation.

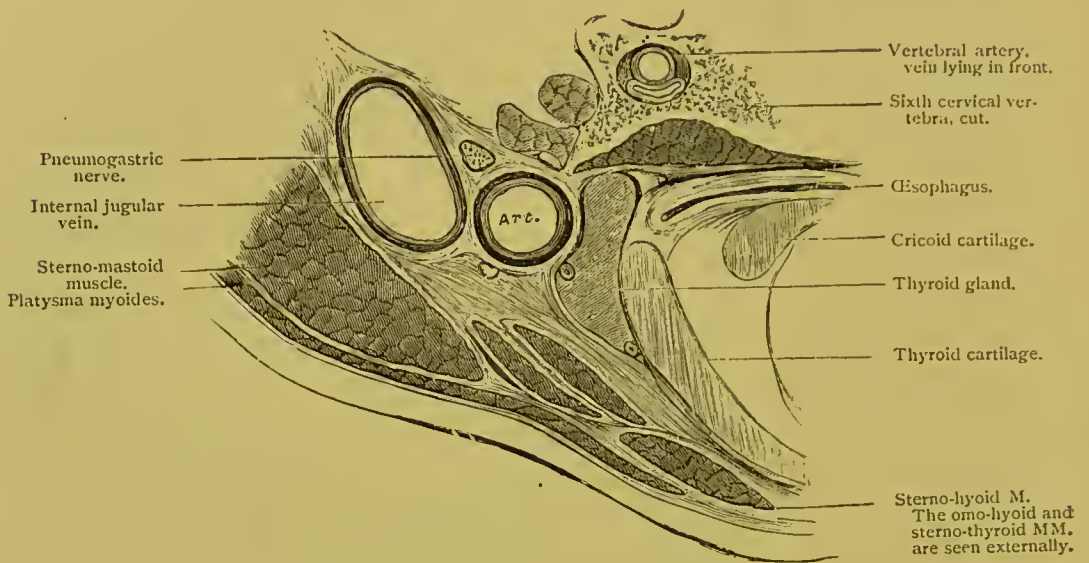

FIG. 67.—Section of parts in relation with the carotid artery at the level of the sixth cervical vertebra.

Direction.—A line drawn from the sterno-clavicular articulation to the mid-point between the angle of jaw and the mastoid process corresponds to the position of the common, and also of the internal carotid artery.

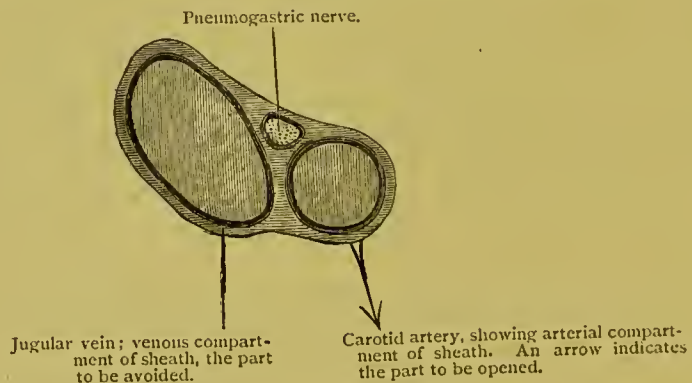


FIG. 68.—Diagram of the carotid sheath.

The main vessel may be tied in any part of its course. It is superficial above and very deeply placed below.

LIGATURE OF THE COMMON CAROTID ARTERY ABOVE THE OMO-HYOID MUSCLE.

Above the omo-hyoid muscle is the seat of election. It is the situation in which to apply the ligature in all cases where it is possible to do so, and where in fact it has been most frequently applied.

Guide.—Line indicated, and inner edge of the sterno-mastoid muscle.

Operation.—Support the shoulders on a pillow. Elevate the chin and turn the head to the opposite side in an extended position. Make an incision of nearly three inches along the inner border of the sterno-mastoid, from the hyoid cornu to a point below the cricoid cartilage (Fig. 73). Divide the skin and platysma, and thus expose the edge of the sterno-mastoid. It may be necessary to secure the sterno-mastoid branch of the superior thyroid artery. Avoid the anterior jugular vein and the venous plexus usually found in this situation. Then incise the deep cervical fascia above the omo-hyoid. Draw the sterno-mastoid muscle outwards, and the omo-hyoid, the thyroid body if exposed, and larynx in the opposite direction. The common sheath will now be laid bare. Open it carefully, keeping well towards the inner side (Fig. 68), otherwise the internal jugular vein may be wounded. The special sheath of the vessel must now be sufficiently opened with the director before attempting to pass the needle. If care be not taken the pneumogastric nerve may be included in the ligature. Push the jugular vein, if visible, outwards with the finger, and compress it in the upper angle of the wound. This will empty it of blood and diminish the risk of wounding it. Pass the needle from without inwards, close around the artery, excluding the pneumogastric nerve, and the descendens noni which usually lies upon the centre of the sheath.

In some instances the artery has been transfixed, and the vein wounded in others. The pneumogastric and sympathetic nerves, as also the descendens noni, have been included in the ligature. To avoid the risk of these accidents, the proper sheath must be opened sufficiently to expose the artery quite distinctly.

LIGATURE OF THE COMMON CAROTID ARTERY BELOW THE OMO-HYOID MUSCLE.

Below the omo-hyoid muscle the artery lies very deeply, overlapped by the sterno-hyoid and sterno-thyroid muscles, and on the left side by the

jugular vein. The recurrent laryngeal nerve and inferior thyroid artery are behind.

Guide.—The line before mentioned. Edge of the sterno-mastoid muscle. After the superficial structures are divided seek the anterior tubercles of the cervical vertebræ, and especially the 6th, or carotid tubercle of Chassaignac.

Operation.—Make an incision, three to four inches long, from a little above the level of the cricoid cartilage to the notch of the sternum, divide the integuments, platysma, and deep fascia, draw the sterno-mastoid muscle outwards. It will be necessary to divide the sternal portion of the sterno-mastoid, and the sterno-hyoid and sterno-thyroid muscles if the vessel have to be secured low down, and then the sheath will become sufficiently exposed. When a ligature has to be applied a little below the crossing of the omo-hyoid, these muscles need only to be retracted towards each margin of the wound.

Now seek the artery, and open its sheath near to the trachea. Pass the needle from without inwards. On the right side the vein is not in danger of injury, but on the left it may overlap the artery (Fig. 66).

The vessel may be readily tied where the omo-hyoid crosses it opposite the cricoid cartilage. In this case the muscle may be either pushed aside or, if in the operator's way, divided without hesitation. The division of the artery into portions above and below the omo-hyoid is perfectly arbitrary, and without anatomical importance. The surgeon will apply the ligature to that portion of the vessel which the circumstances of the case demand, irrespective of the position of the omo-hyoid muscle.

Cerebral symptoms, of which the most common is hemiplegia of the opposite side of the body, frequently follow the operation, and are a common cause of death. Suppuration of the aneurismal sac is sometimes a consequence of the operation.

A few cases are recorded in which both common carotid arteries were tied, with an interval between the operations. Judging by the cases published, the mortality has been, comparatively speaking, small.

The collateral circulation is very abundant; so much so, that pulsation may very shortly reappear in the sac. The blood comes almost entirely from the branches of the subclavian on the same side of the neck (Fig. 60).

Collateral Circulation (Fig. 60).

CARDIAC SIDE.		DISTAL SIDE.
<i>Inferior thyroid from thyroid axis of subclavian</i>	} with {	<i>Superior thyroid of external carotid.</i>
<i>Profunda cervicis of superior intercostal</i>	} with {	<i>Princeps cervicis of occipital deep branch.</i>
<i>Superficial cervical branch of transversalis colli (thyroid axis)</i>	} with {	<i>Superficial branch of princeps cervicis.</i>
<i>Vertebral</i>	with	<i>Opposite vertebral in skull.</i>
<i>Muscular branches of vertebral (where the artery curves round articular process of atlas)</i>	} with {	<i>Deep branch of princeps cervicis of occipital.</i>
<i>Branches of external carotid with vessels of opposite side.</i>		
<i>Internal carotid, by anterior communicating of anterior cerebral with opposite internal carotid in skull.</i>		

LIGATURE OF THE EXTERNAL CAROTID ARTERY.

Indications.—The vessel has been tied on account of traumatic aneurism, erectile tumours, prior to the removal of tumours of the parotid and submaxillary regions, for gunshot and other wounds, and on several occasions for hæmorrhage from cancer of the tongue. It may be accepted as a rule that when there is room it is better to tie the external carotid for uncontrollable hæmorrhage from any of its branches rather than the common carotid, the ligature of which statistics would seem to prove about ten times more fatal. It will always be difficult, and may be impossible, to determine whether an aneurism in this region be connected with the internal carotid, the external carotid, or one of its branches.

Notwithstanding that the external carotid artery gives off many and large branches (Fig. 69), it has been successfully tied in several cases where the common carotid, a much more dangerous alternative, must otherwise have been ligatured. It is remarkable that in spite of the close proximity of these large branches, secondary hæmorrhage is very rare after this operation. The region of the body is one well adapted for rapid repair.

Surgical Anatomy.—The external carotid at its origin, opposite the upper border of the thyroid cartilage, is more internal and anterior than the internal carotid (Fig. 70). The names are given from the distribution of the two vessels. The artery ascends towards the interval between the external

auditory meatus and the temporo-maxillary articulation, and then turning outwards enters the parotid gland, in which it continues till it terminates on the inner side of the neck of the lower jaw by dividing into the temporal and internal maxillary arteries. In its first stage, before entering

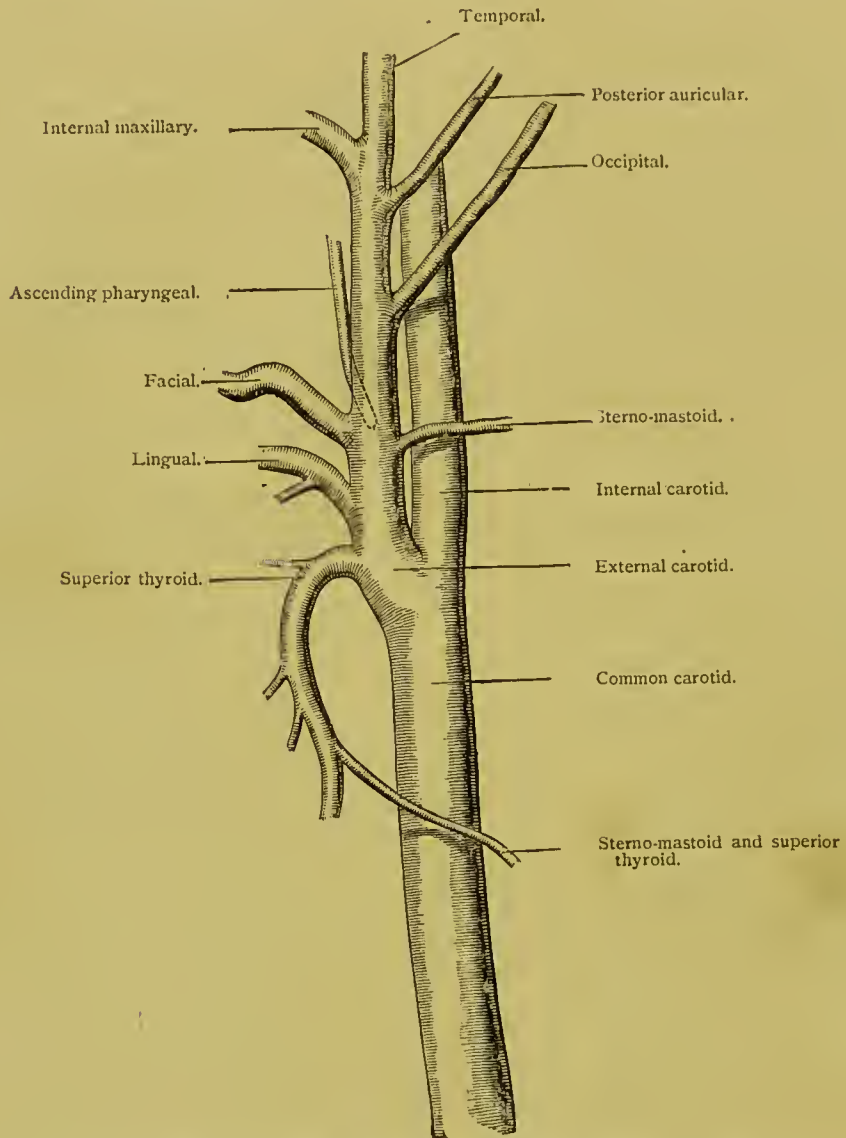


FIG. 69.—Diagram of the left common, external, and internal carotid arteries.

the parotid gland, it is comparatively superficial. It is here covered by the skin, platysma, and the cervical fascia. The lingual and facial veins, joining the internal jugular, lie in front (Fig. 71). The posterior belly of

the digastric and the stylo-hyoid muscle cross the artery from one inch to one inch and a-half above the bifurcation, and the hypoglossal nerve a little lower. The vessel rests on the pharynx, the superior laryngeal nerve, stylo-glossus and stylo-pharyngeus muscles, glosso-pharyngeal nerve, and deeper portion of the parotid gland. The origin of the internal carotid, the internal jugular vein, and the pneumogastric nerve are on the outer side. The superior cornu of the thyroid cartilage, the great cornu of the hyoid bone, and the side of the pharynx, lie on the inner side (Figs. 66, 70). The artery usually gives off eight important branches, which have a wide area of distribution (Fig. 69).

Guide.—A line corresponding to the anterior margin of the sternomastoid muscle, and extending from the tip of the ear to the extremity of the great cornu of the hyoid bone. The position of the incision will be parallel to and half an inch internal to that for the internal carotid artery.

Operation.—The external carotid artery may be tied between the points of origin of the superior thyroid and lingual arteries, the place of election, or at some higher point if necessary. At the lower position there is an interval often of three-quarters of an inch between the superior thyroid and lingual arteries; but the arrangement of the branches varies. There is seldom sufficient space between the bifurcation and origin of the superior thyroid artery in which to apply a ligature. In a large proportion of cases this vessel is given off immediately, and in the rest not more than half an inch above the bifurcation of the common carotid. The operation will be similar to that for the internal carotid. Make an incision in the direction of the vessel about three inches long from opposite the middle of the thyroid cartilage to the angle of the jaw (Fig. 70). The centre of the incision should correspond to a point half an inch to one inch above the thyroid cartilage, according to the part of the vessel it is desired to ligature. Then divide the skin, platysma, and fascia. The posterior belly of the digastric will now be exposed, and must be drawn upwards. The ligature, if there be interval sufficient, may pass round the vessel before it gives off the superior thyroid branch, but very frequently there will be no space in which to do this. Carefully avoid including the superior laryngeal nerve which crosses obliquely inwards beneath and internal to the external carotid artery near its origin. Above the digastric muscle the vessel is

scarcely accessible, and the wound made in order to reach it would, of necessity, divide the more important branches of the facial nerve.

The incision which is made to secure the external carotid also suffices for the ligature of the superior thyroid artery, and somewhat higher up

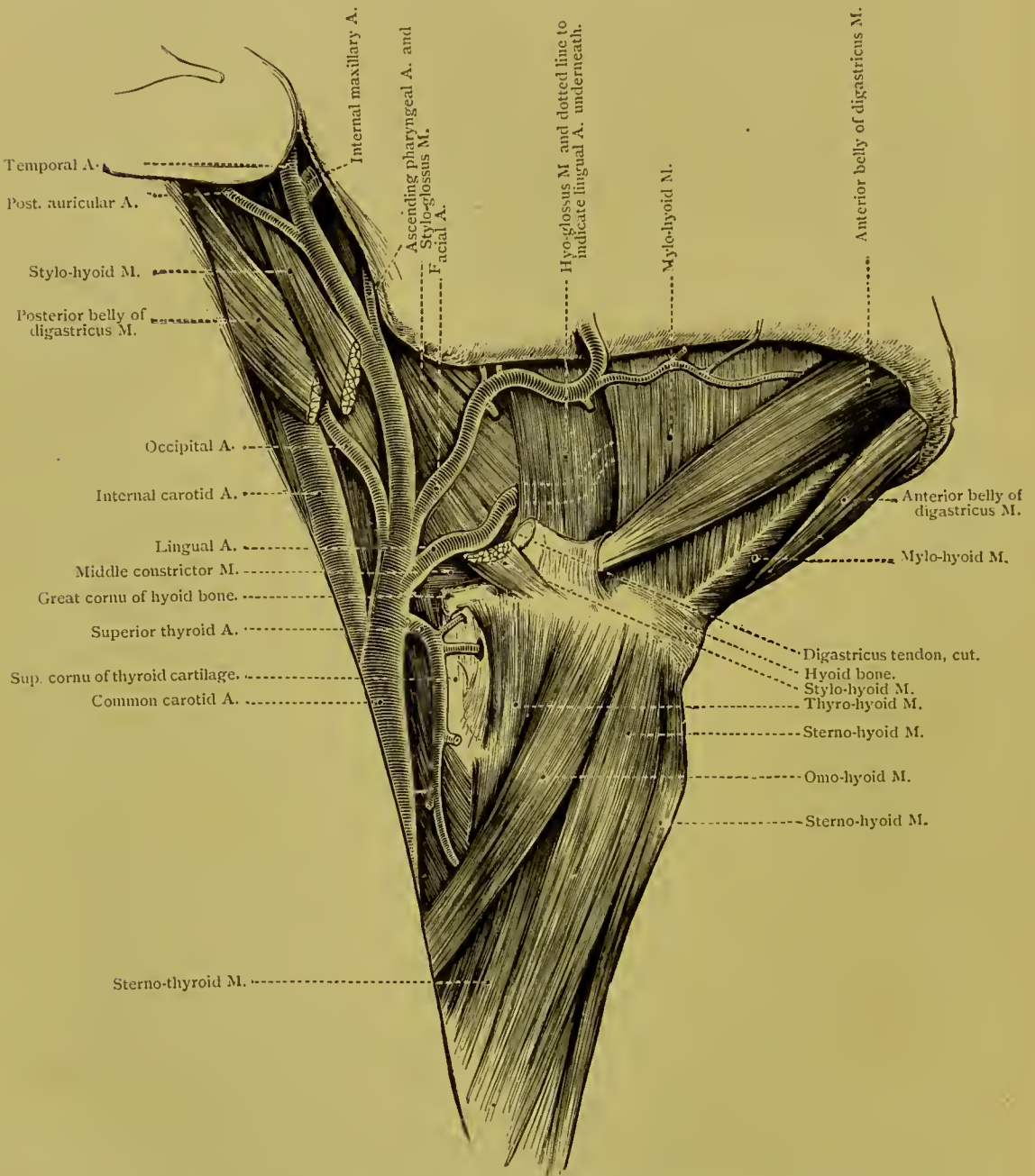


FIG. 70.—Diagram illustrating the position of the external and internal carotid arteries, and principal branches of the former.

for the first stages of the occipital, lingual, and facial arteries, which arise from the main trunk near its commencement, and are all comparatively superficial at first (Fig. 70).

INTERNAL CAROTID ARTERY.

Indications.—This artery very rarely requires an operation. Wounds in the neck by gunshot or otherwise, intra-cranial hæmorrhage, aneurism, may give occasion for its ligature, and it has been tied prior to the removal of certain tumours. The artery is somewhat closely applied to the posterior and outer side of the tonsil. In operations involving the tonsil it may be wounded. It has been wounded in incising an abscess of this gland, and serious hæmorrhage has occurred from the artery being opened into by ulceration during unhealthy inflammation of the tonsil. The important relations of the artery above the angle of the jaw render it very difficult to reach, but in the case of wound an attempt should be made to expose the vessel and to secure it above and below the seat of injury. The vessel has been very rarely ligatured alone, more frequently the external and common carotid arteries have been tied in addition.

Anatomical relations.—The internal carotid is the larger division of the common trunk, and is a direct continuation of it (Figs. 69, 70). It usually gives off no branches in its cervical part. Its first portion is comparatively superficial, but it soon becomes very deeply placed. The internal carotid lies outside and rather posterior to the external carotid.

The last inch and a-half of the common carotid and first inch of the internal and external carotid arteries are uncovered by muscles, excepting the platysma. The posterior belly of the digastric muscle and the stylo-hyoid, about half-an-inch in width, cross the two last-named vessels nearly an inch and a-half above the bifurcation.

Guide.—Upper part of a line drawn from the sterno-clavicular joint to a point just in front of the tragus of the ear.

Operation.—The internal carotid may be secured near its origin by means of an incision in the line of direction already indicated as that of the common trunk, similar, but slightly more external, to that made for the external carotid artery. The same superficial structures will require to be divided as in the case of the external carotid. The centre of the

incision should be from half to three-quarters of an inch above the upper border of the thyroid cartilage. When the vessel has been exposed pass the needle round it from the outer side, taking care to avoid the internal jugular vein and pneumogastric nerve externally, the external carotid internally, and the hypoglossal nerve crossing the vessel superficially about one inch above the bifurcation. The ascending pharyngeal artery is also in close relation with the internal carotid.

LIGATURE OF THE SUPERIOR THYROID ARTERY.

Indications.—The thyroid artery is often divided in cases of suicidal wound, and should then be secured with a double ligature. If wounded close to its origin it may be necessary to secure the external carotid artery as well as the peripheral end of the divided vessel in order to arrest the hæmorrhage. The artery has been ligatured with a view to check the growth of bronchocele.

Surgical Anatomy.—This artery is the first branch of the external carotid. It arises from its anterior and inner aspect close to the bifurcation (Figs. 65, 69, 70), opposite the thyro-hyoid space. First it ascends slightly, and after turning forwards passes downwards and inwards to the thyroid gland. It is slightly anterior and internal to the external carotid artery, and is covered by the skin, platysma, cervical fascia, and some small veins, also by the sterno-hyoid, sterno-thyroid, and omo-hyoid muscles, and a branch from the descendens noni nerve.

Guide.—The inner edge of the sterno-mastoid muscle.

Operation.—Make an incision an inch and a-half in length along the inner border of the sterno-mastoid. The centre of the wound should correspond with the thyroid notch. After the superficial structures have been divided a plexus of veins will be exposed. They will probably require to be tied and divided. The artery may then be readily exposed, and a ligature applied at the required point, which will vary between half an inch below or above the level of the bifurcation of the common carotid.

LIGATURE OF THE LINGUAL ARTERY.

Indications.—The vessel may be tied for lingual hæmorrhage, and as a

preliminary to excision of the tongue. It has also been ligatured to arrest the growth of cancer, and in cases of macroglossia.

Anatomical relations.—The origin of the lingual artery (Figs. 70, 71) is nearly opposite the great cornu of the os hyoides, a little

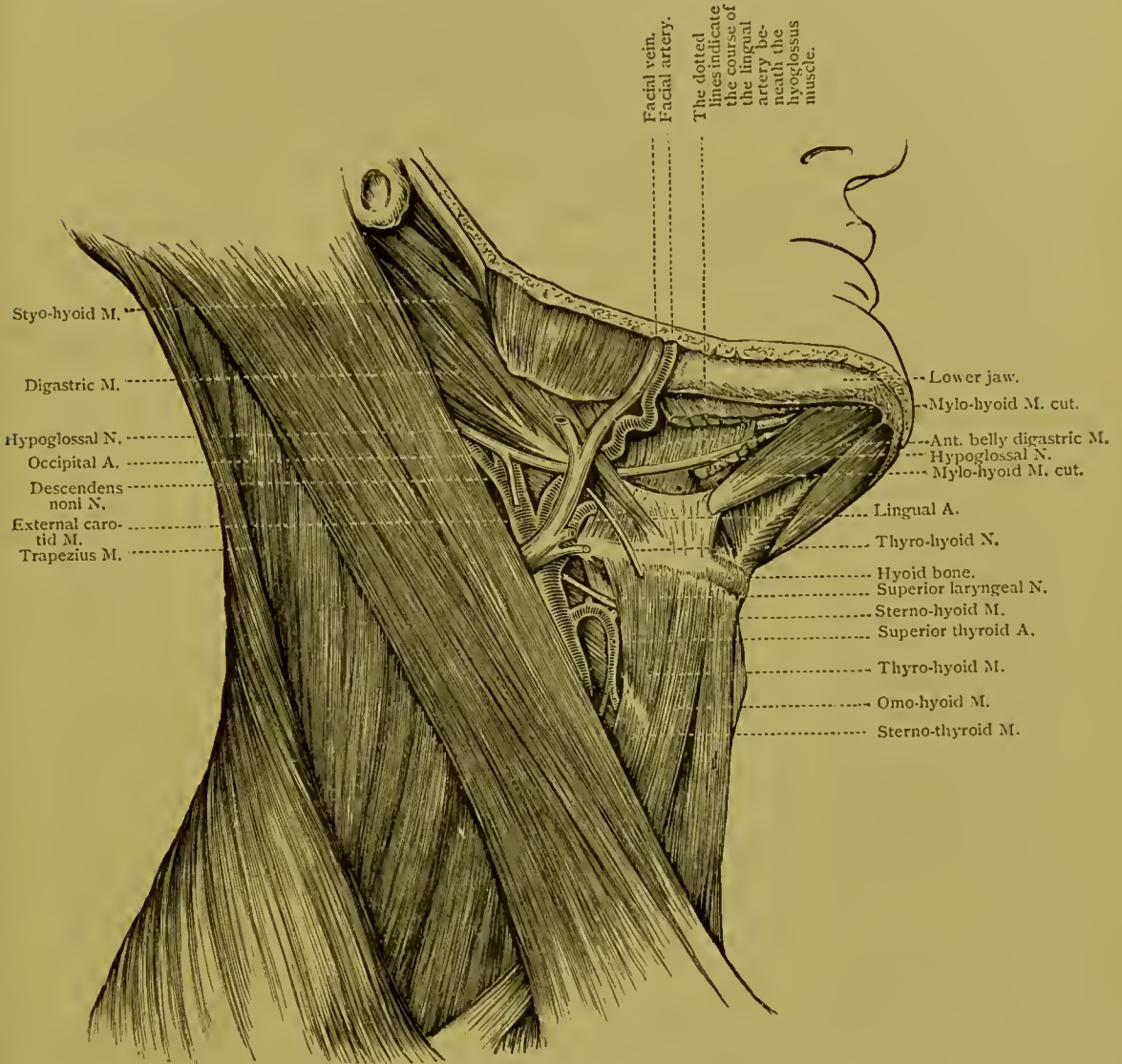


FIG. 71.—Principal branches of the external carotid artery.

above the origin of the superior thyroid artery, or from half to one inch above the bifurcation. It may arise in common with the inferior thyroid, or with the facial artery. It first ascends a little, and then

passes inwards on the middle constrictor of the pharynx and genio-hyoglossus to the outer edge of the hyoglossus muscle, with a curve downwards, the concavity lying above a corresponding convexity in the course of the superior thyroid artery. It next passes upwards and inwards beneath the digastric, stylo-hyoid, and hyoglossus muscles, the last separating it from the hypoglossal nerve which at first lies a little above it. The dorsalis linguæ is given off just in front of the posterior border of the hyoglossus muscle. The continuation of the artery, now often called ranine, ascends to reach the base of the tongue, and then passes horizontally forwards between the genio-glossus and lingualis muscles, above the frænum. In this stage it comes into close relation with the hypoglossal nerve. In the first stage of its course the artery is covered by the skin, platysma, cervical fascia, lymphatic glands, plexus of veins, and by the submaxillary gland, more especially in old people. The hypoglossal nerve, the digastric muscle and its tendon are superficial to it. In the second stage it is covered in addition by the hyoglossus muscle. Two venæ comites accompany the lingual artery, and a satellite vein follows the course of the lingual nerve. The ranine vein lies on the inferior surface of the tongue superficial and external to the third stage of the artery. The artery varies in its place of origin, sometimes coming off with the facial or superior thyroid arteries. This affords a reason against applying a ligature close to its origin.

Guide.—The great cornu of the hyoid bone, and the tendon of the digastricus muscle.

The artery may be tied in two places. The operation is one very much easier to perform on the dead than the living subject.

Operation in the first stage.—To secure the vessel near its origin, above the great cornu of the hyoid bone, make an incision slightly convex downwards, an inch and half long, corresponding to, and just above, the great cornu (Fig. 73), and extending from the body of the hyoid bone to the edge of the sterno-mastoid muscle. Divide the skin, platysma, and fascia, raise up the submaxillary gland and hypoglossal nerve, and carefully divide the outer margin of the hyoglossus muscle a line above the great cornu, or the muscle may be retracted towards the middle line. Avoid injuring the veins at the external angle of the wound. Avoid the facial vein in the septum between the submaxillary and parotid glands.

Operation in the second stage.—To reach the artery in the submaxillary triangle, make an incision two inches long, convex downwards, and nearer the median line than in the other case. It should be half-way between the jaw and the hyoid bone, and extend posteriorly to the angle of the jaw. Expose and raise up the submaxillary gland. Seek and draw upwards the hypoglossal nerve. Divide the hyoglossus muscle within the apex of the digastric triangle, immediately beneath the position of the hypoglossal nerve.

In the first operation the artery is often tied very near its origin, which is objectionable. At the place selected for the second, the dorsalis linguæ has generally been previously given off, and therefore hæmorrhage from the vessels at the base of tongue will not in that case be arrested. The operation, however, is easier.

LIGATURE OF THE POSTERIOR AURICULAR ARTERY.

This is one of the smallest branches of the external carotid artery. It arises in the substance of the parotid gland nearly opposite the apex of the mastoid process. It ascends along the superior margin of the posterior belly of the digastric muscle to the interval between the mastoid process and external auditory meatus, where it divides into two terminal portions, besides giving off several other branches (Figs. 70, 72). The artery has been wounded in the operation of cutting down on the facial nerve after its exit from the sterno-mastoid foramen, and it has been tied for aneurism by anastomosis on the pinna. The vessel possesses little surgical importance. It may be reached by a vertical incision midway between the external auditory meatus and front of the mastoid process.

LIGATURE OF THE FACIAL ARTERY.

Indications.—This artery may be wounded, or prove the subject of traumatic aneurism.

Surgical Anatomy.—The artery is divided into two stages, a cervical and a facial (Figs. 70, 71, and 72). In the first stage it ascends from its origin about an inch above the carotid bifurcation, immediately above the lingual artery (Fig. 69), or sometimes in common with it, under cover of

the skin, platysma and cervical fascia, digastric and stylo-hyoid muscles, hypoglossal nerve and a portion of the submaxillary gland. Under cover of the lower jaw it is imbedded in the submaxillary gland, and then passes downwards to turn subcutaneously around the border of the maxilla, whence it ascends as the facial portion to the internal angle of the eye, giving off many branches. The vein lies immediately behind the artery as it passes round the jaw (Fig. 71).

Operation.—The vessel can be tied near its origin like any of the branches of the external carotid after first exposing this vessel. The centre of the incision should be a quarter of an inch above the hyoid bone. This proceeding can rarely be required. It is usually secured, as it passes over the

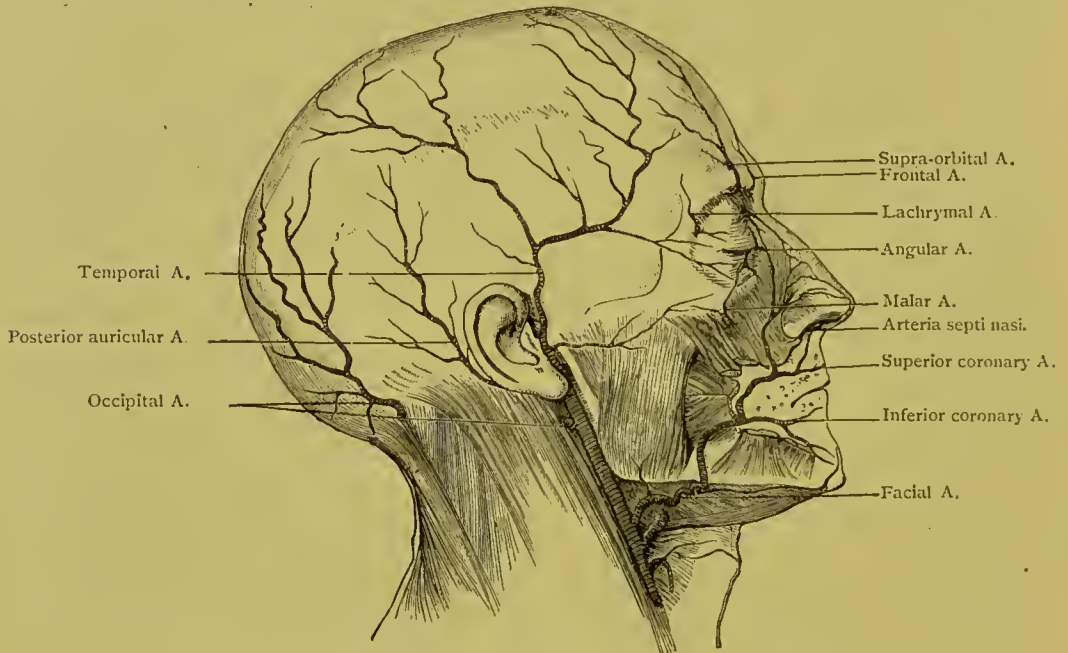


FIG. 72.—Distribution of the arteries on the face and head.

ramus of the jaw, in a groove just in front of the masseter, about an inch anterior to the angle. Its position will be better defined and the pulsations felt more distinctly by causing the patient to bring the masseter into action by firmly closing the jaws. At the point indicated make an incision along the inferior border of the lower jaw an inch long, or a nearly vertical incision in the direction of the vessel (Fig. 73) of the same length. Divide the skin and platysma carefully. The artery will be felt in the fatty tissue under-

neath, rolling under the finger. Before passing the ligature the vessel should be separated from its vein, which lies close upon its posterior surface.

LIGATURE OF THE OCCIPITAL ARTERY.

Indications.—This vessel can scarcely require ligature, except on account of a wound of the scalp causing troublesome hæmorrhage, or possibly a traumatic or cirroid aneurism of the scalp.

Surgical Anatomy.—Its position as it emerges on the scalp, at a point midway between the mastoid process and the occipital protuberance, is clearly indicated in Fig. 72. The artery is given off by the external carotid (Figs. 69, 70) nearly opposite the lingual and facial arteries. It passes upwards and backwards beneath the posterior belly of the digastric to reach a groove in the mastoid process at the inner edge of the groove for the digastric muscle. It then proceeds somewhat horizontally backwards covered by a layer of strong fascia, also by the sterno-mastoid, and behind this by the splenius capitis, deeper by the trachelo-mastoid, and deeper still by the mastoid process and origin of the posterior belly of the digastric. It passes over the insertions of the obliquus superior and complexus muscles, pierces the trapezius muscle, and ascends obliquely upwards to ramify over the occipital region. After emerging from beneath the mastoid process the artery may be reached in a space bounded above by the attachment of the splenius capitis to the superior curved line and mastoid process, in front by the trachelo-mastoid, and behind by the complexus. In this triangular space the artery is only covered by the scalp and splenius capitis muscle. The artery lies on the superior oblique muscle, which separates it from the occipital bone.

Operation.—To reach it in the first stage an incision like that for ligature of the external carotid artery may be made, or the tissues may be divided in the course of the posterior belly of the digastric muscle, beneath which the artery will be found. Care must be taken to avoid the hypoglossal nerve, which turns round its first stage, and gives off at this point the descendens noni (Fig. 71). Beneath the mastoid process the artery lies too deep to be reached.

A horizontal incision two inches in length may be made from the tip of the mastoid process directly backwards and slightly upwards. The

posterior border of the sterno-mastoid muscle and the aponeurosis covering it must be divided, and then the splenius capitis. Very often the fibres of the trachelo-mastoid must also be severed. On search being made in the anterior angle of the wound the vessel will be found between the mastoid process and the transverse process of the atlas as it emerges beneath the posterior belly of the digastric. The occipital vein at this point receives large mastoid branches, which must be avoided.

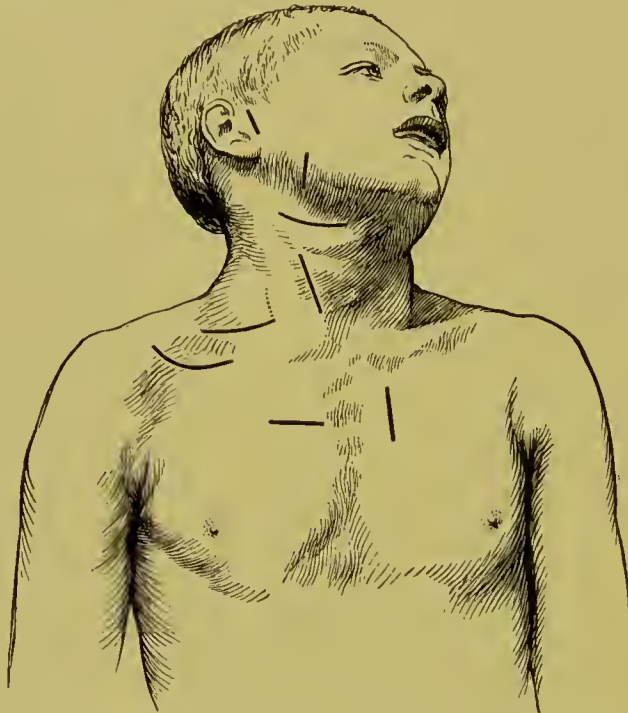

FIG. 73.—Indicates the positions of the lines of incision made for the purpose of ligating the temporal, facial, lingual, carotid (above omo-hyoid), subclavian, axillary (first stage or below clavicle), and internal mammary arteries.

LIGATURE OF THE TEMPORAL ARTERY.

Indications.—This vessel will most frequently require ligature on account of injury either of an accidental nature or after arteriotomy. An arterio-venous aneurism has also sometimes formed in the temporal region, and necessitated the ligation of the artery.

Surgical Anatomy.—In the first part of its course the vessel lies deeply in the substance of the parotid gland. On emerging from this it may be felt

beating half-way between the condyle of the jaw and the tragus of the ear, just behind the root of the zygoma (Figs. 69, 70, 72).

Operation.—At this point a vertical incision an inch long should be made in order to expose the artery (Fig. 73). It lies anterior to, but more deeply placed, than the temporal vein, and near to the auriculo-temporal nerve. The vessel must be thoroughly exposed before passing the ligature round it, as the vein or nerve would otherwise run the risk of being included in the noose.

Its anterior branch is the one selected for arteriotomy. In this operation the vessel may be exposed through a small wound and partially divided. When a sufficient amount of blood has been drawn the artery should be cut completely across. The ends retract, and a pad and bandage usually suffice to prevent any further bleeding.

LIGATURE OF THE ANTERIOR DIVISION OF THE MIDDLE MENINGEAL ARTERY.

Indications.—In fractures of the skull extending through the temporal region, the middle meningeal artery may be lacerated, and sometimes extensive extravasation, causing severe symptoms, takes place from it between the dura mater and the skull. This may escape through a fissure in the bone into the temporal fossa, which then becomes infiltrated with the extravasated blood. The close relation of the artery to the bone, which it grooves deeply, or in some cases lies enclosed in a bony canal, and the liability to fracture of the internal table, explain the frequent injury to this vessel from severe blows upon the head. Aneurism of the middle meningeal artery has been observed in a few cases. In three, the tumour presented externally, and was mistaken for a sebaceous tumour. Fatal hæmorrhage took place on an attempt being made to extirpate. In one case of aneurism, ensuing apparently upon a fall on the head, Bardeleben successfully tied the common carotid.

Anatomical relations.—The artery is the largest branch of the internal maxillary, and the most important source of blood supply to the dura mater. It ascends obliquely from its origin inside the neck of the lower jaw to the foramen spinosum. Having entered the skull, it passes beneath the dura mater to the middle fossa, where it divides into two terminal

branches. The anterior branch of the vessel is the larger. It passes upwards on the great wing of the sphenoid, and in a deep groove or canal in the anterior inferior angle of the parietal bone, after which it divides into branches to the dura mater. The posterior branch passes directly backwards across the squamous portion of the temporal bone.

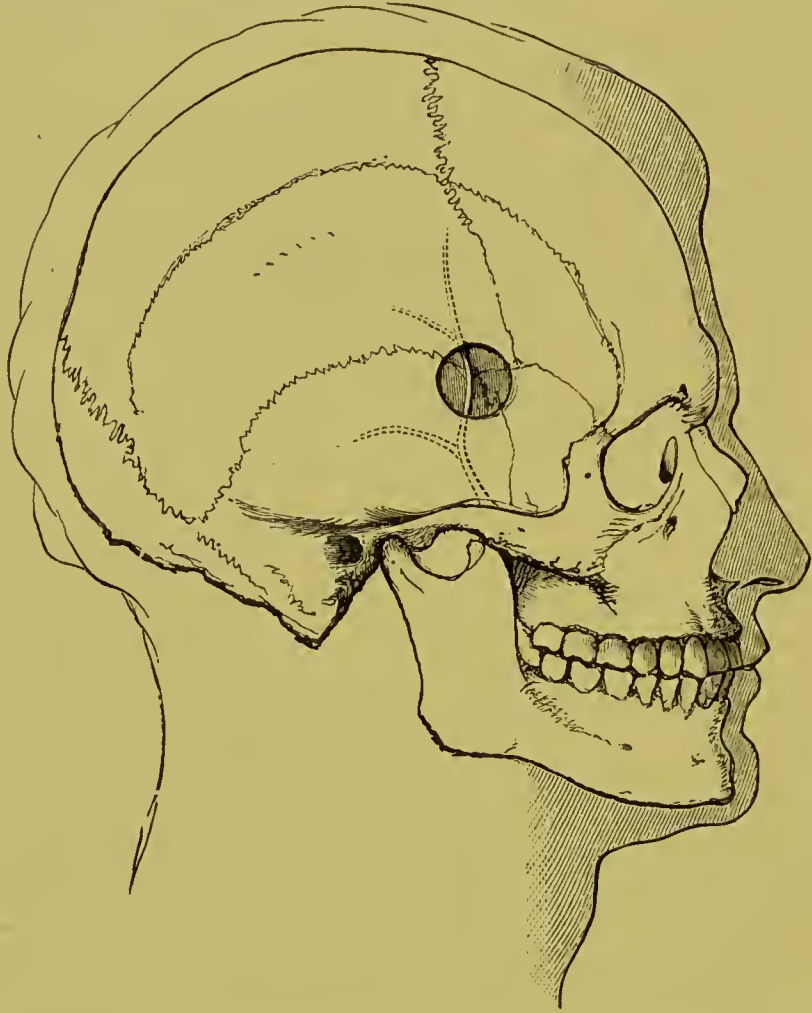


FIG. 74.—Relations of the middle meningeal artery to the surface of the skull. Position of the trephine opening which may be made to expose the anterior branch.

Operation.—The anterior division has been several times ligated on account of intracranial bleeding. The position in which it may be most readily exposed is where it crosses the anterior inferior angle of the parietal bone (Fig. 74). This point may be determined by the intersection of a

horizontal line drawn two inches above and parallel to the zygoma, with a vertical one an inch behind the posterior superior border of the malar bone. A sufficiently large external incision, either flap-shaped, vertical or crucial, must first be made, and the fibres of the temporal muscle divided. This often necessitates a deep wound, as the muscle may be found infiltrated with blood pent up beneath its strong fascia. When the skull is exposed, the crown of the trephine should be applied, always keeping in mind the very unequal thickness of the bone here, and its probable thinness at some part of the circle. After the circle of bone has been removed, the bleeding vessel may be discovered and ligated, or pressure applied, the clot present allowed to escape, and the cause of the brain compression removed or abated. The operation is difficult and its result uncertain. It has been successfully performed by Hueter, Cock, and Socin. Sir P. Hewett alludes to two successful instances of its performance at St. George's, and Mr. Erichsen to one in University College Hospital.

LIGATURE OF THE ARTERIES OF THE LOWER EXTREMITIES
AND OF THE PELVIS.

PLANTAR ARTERIES.

THE plantar arteries may receive injury, and require to be ligatured, in wounds of the sole of the foot. The woodcut represents their position in a transverse section of the foot made through the cuneiform and cuboid bones.

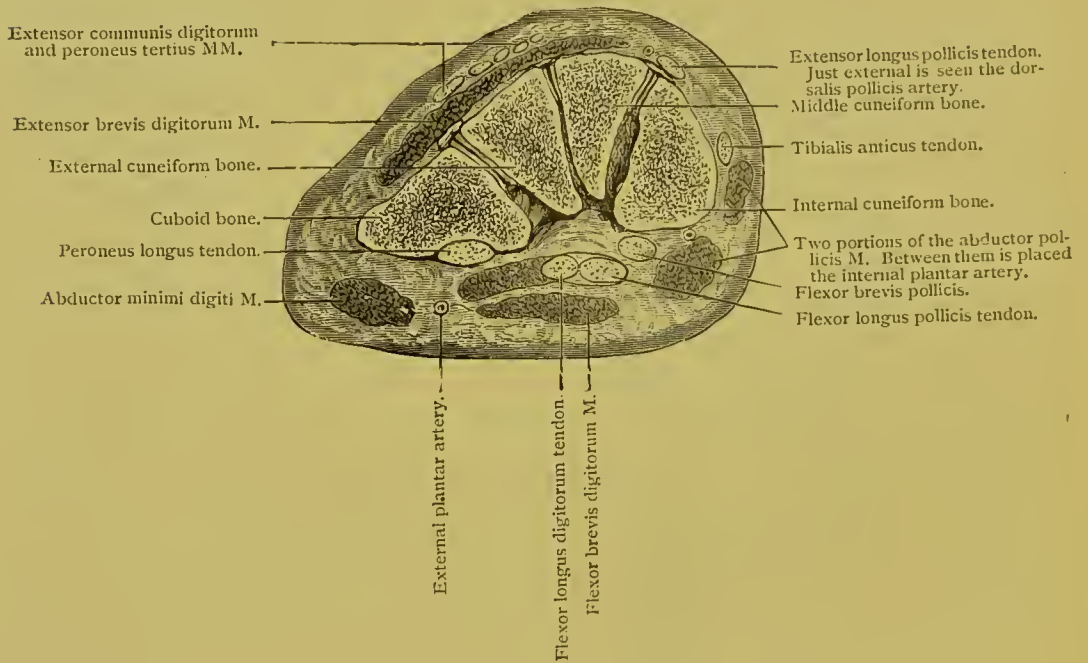


FIG. 75.—Median transverse section of the foot.

The internal plantar is an inconsiderable vessel. It passes forward above the abductor pollicis muscle to terminate in digital and other small branches.

The external plantar is much larger. It first passes obliquely outwards and forwards towards the base of the fifth metatarsal bone, closely following the outer border of the flexor longus digitorum. Above it is the acces-

sorius muscle, and below are the flexor brevis digitorum and plantar fascia. Further forward, in the part where the section is made, the artery lies between the flexor brevis on the inner side and the abductor minimi digiti muscle outside. It terminates by becoming continuous with the communicating branch of the dorsalis pedis artery, to join which it turns inwards as far as the interval between the first and second metatarsal bones, thus forming the plantar arch. The vessel is deeply seated between the interossei above, and the lumbricales, flexor tendons, and adductor pollicis below. Its course describes a curve whose convexity looks forwards and outwards. It is also curved transversely and antero-posteriorly to correspond with the lateral and antero-posterior arches of the foot.

LIGATURE OF THE DORSALIS PEDIS ARTERY.

Indications.—This artery can seldom require ligature except for accidental injury. Spontaneous aneurism has, in a few instances, formed on it.

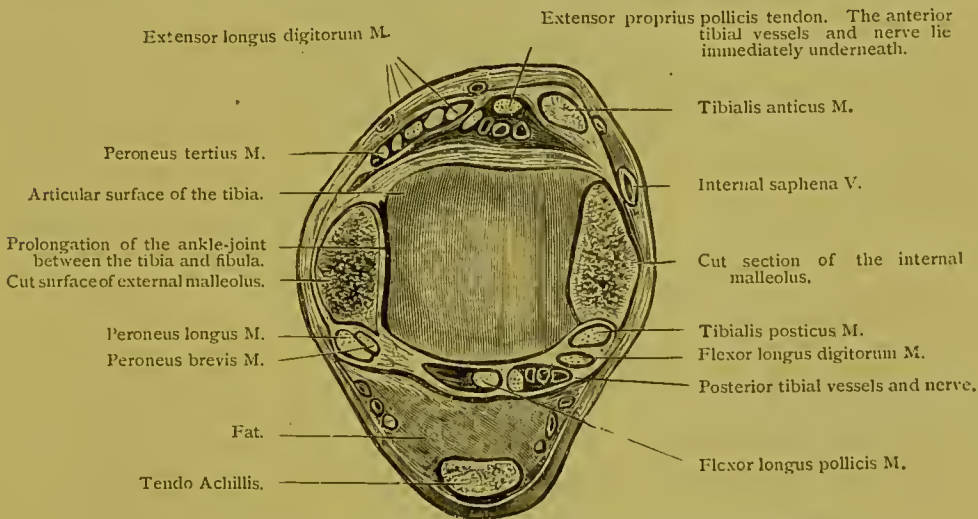


FIG. 76.—Transverse section of the right ankle through the malleoli.

Surgical Anatomy.—It descends in the interval between the extensor longus pollicis and extensor longus digitorum tendons from the front of the ankle-joint to the mid-point between the first and second toes (Figs. 76, 78). The vessel is covered by a thick fascia, and crossed near its termination by the innermost tendon of the extensor brevis digitorum. The nerve lies close upon the outer side.

Guide.—A line drawn from the mid-point of the ankle as measured from malleolus to malleolus, to the middle of the first interosseous space. The tendon of the extensor pollicis muscle on the inner side is the best indication of the position of the artery.

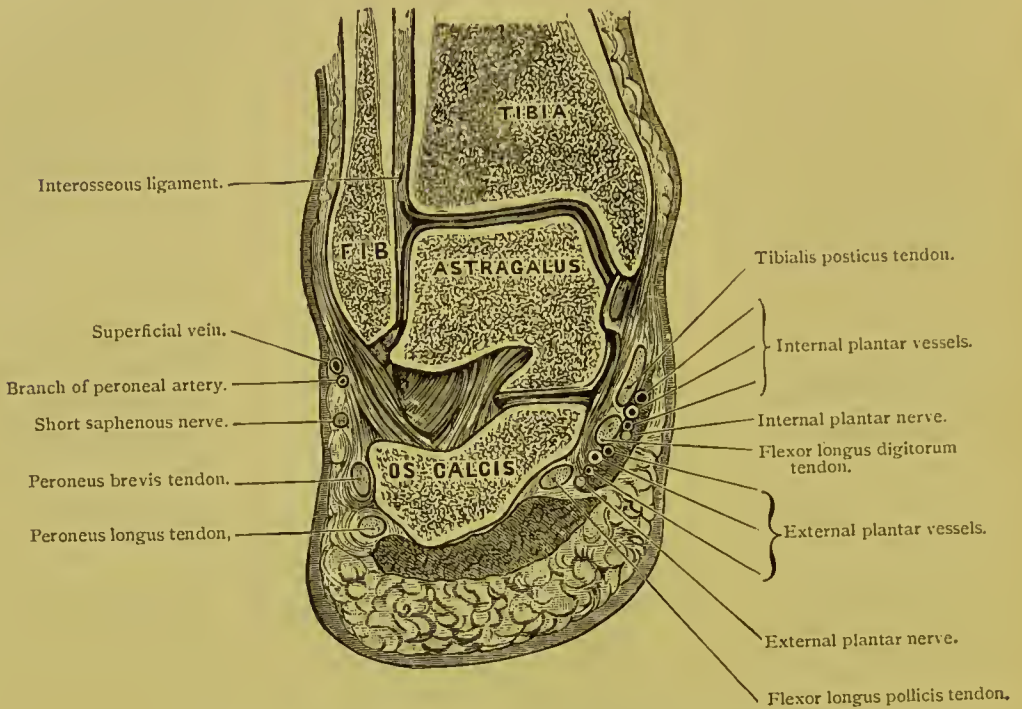


FIG. 77.—Vertical section through the ankle-joint.

Operation.—Make an incision, from one to one and a half inches long (Fig. 80), about a quarter of an inch external to the extensor pollicis tendon, or midway between this tendon and the innermost tendon of the extensor longus digitorum. Divide the skin and fasciæ. The vessel surrounded by fatty cellular tissue may then be exposed and can be readily secured.

LIGATURE OF THE ANTERIOR TIBIAL ARTERY.

Indications.—Wound, aneurism. The anterior tibial artery can be tied in any part of its course. The occasion will probably be a wound, as aneurism is exceedingly rare. In the upper part the vessel lies deeply upon the interosseous membrane, lower down being comparatively super-

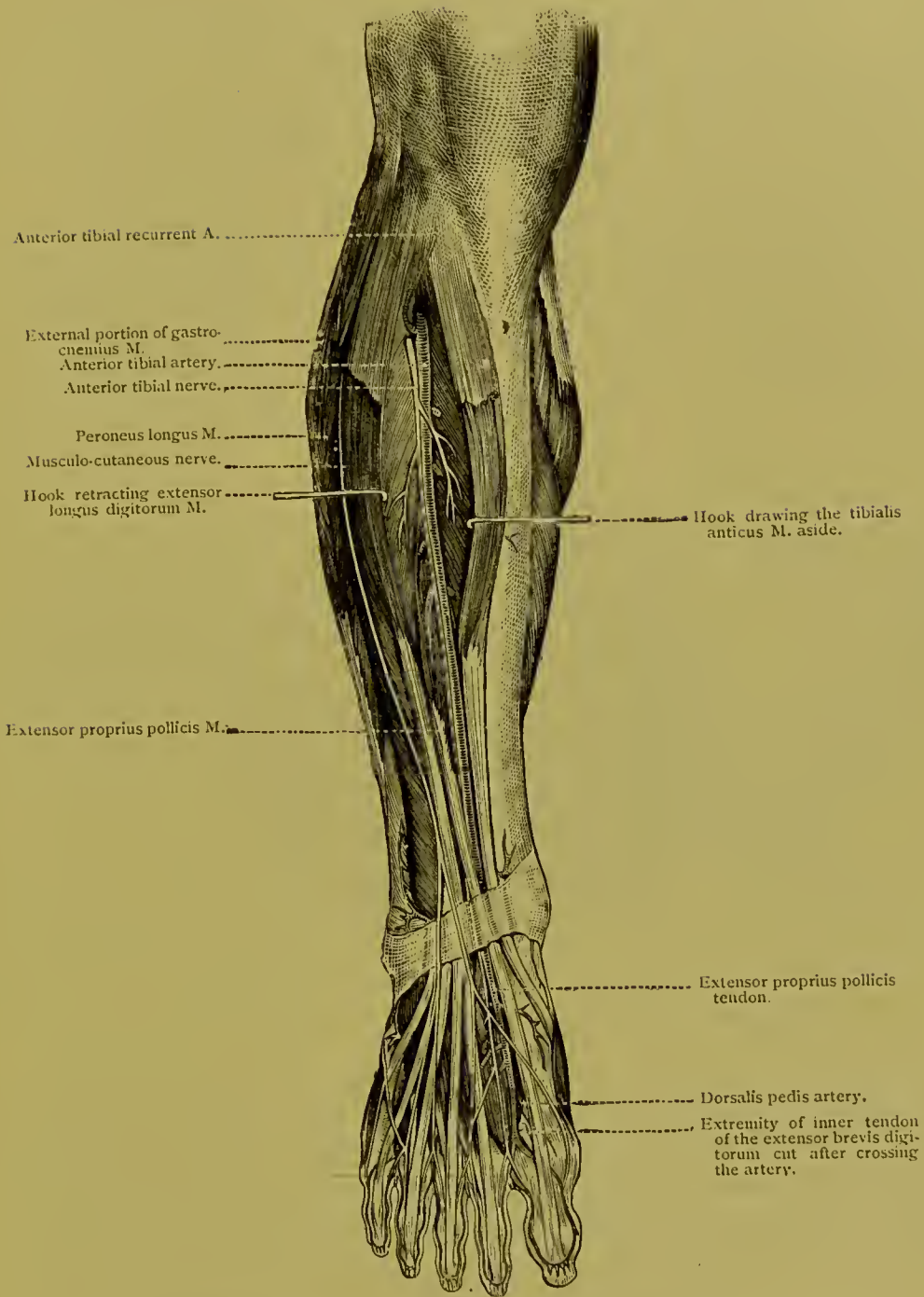


FIG. 78.—Anatomical relations of the anterior tibial and dorsalis pedis arteries.

ficial. Near the ankle-joint we may expose it by operation, but it is very undesirable to seek it at a point where it is crossed by the extensor proprius pollicis tendon and covered by the annular ligament. The operation is rarely performed. Spontaneous aneurism of the arteries below the knee is very uncommon. Traumatic aneurisms are occasionally observed.

Surgical Anatomy.—The artery first pierces the upper border of the interosseous membrane about the level of the lower margin of the tuberosity of the tibia, and upon this membrane it afterwards lies in the upper two-thirds of its course. It is accompanied by two veins. The anterior

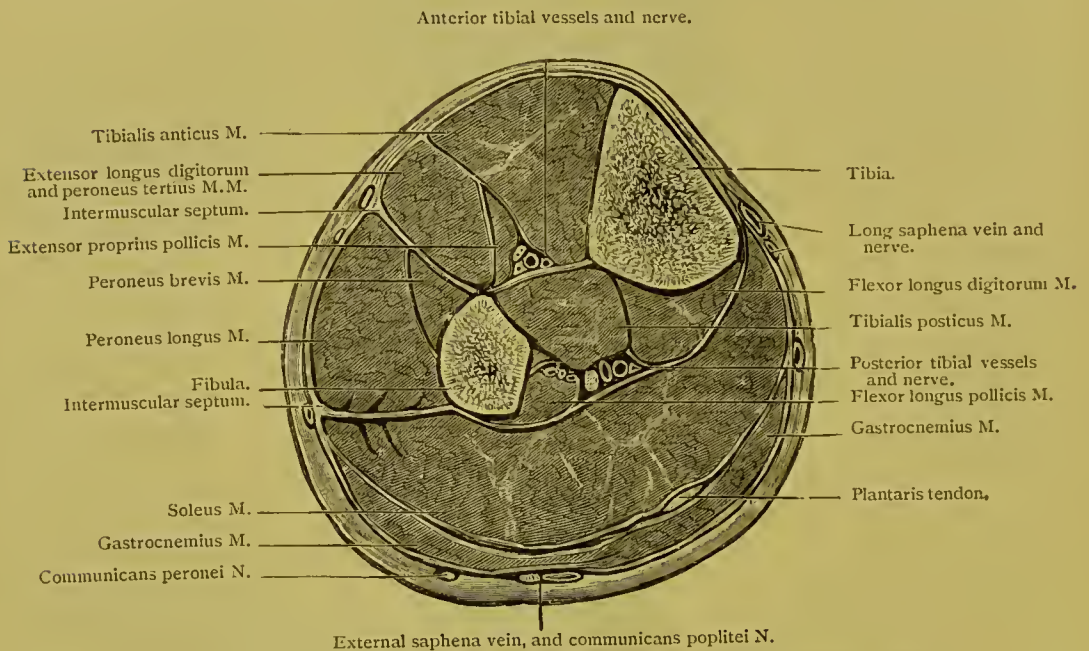


FIG. 79.—Transverse section through the middle of the right leg.

tibial nerve is closely applied to the vessel throughout (Fig. 78). In the lower third, as it descends on the outer surface of the shaft, and the front of the lower extremity of the tibia, it becomes more and more superficial. Where the artery lies upon the interosseous membrane it is very deeply placed. In front of the ankle nothing but the skin and fascial layers cover it.

In the upper fourth of its course the artery lies between the tibialis anticus and extensor longus digitorum, in the middle two-fourths between

the tibialis anticus and extensor proprius pollicis. A little above the ankle-joint the tendon of the last-named muscle crosses over to the inner side of the artery, so that in the lower fourth the artery lies between the tendons of the extensor proprius pollicis and extensor longus digitorum muscles (Fig. 78).

Direction.—A line drawn from the mid-point between the head of the fibula and tubercle of the tibia to the mid-point between the malleoli corresponds to the direction of the vessel, and more or less exactly to the interstice between the tibialis anticus and extensor digitorum muscles, according to the degree of muscularity of the individual (Fig. 80).

The vessel may be secured at any part of its course. It is deeply placed above, and is comparatively superficial below.

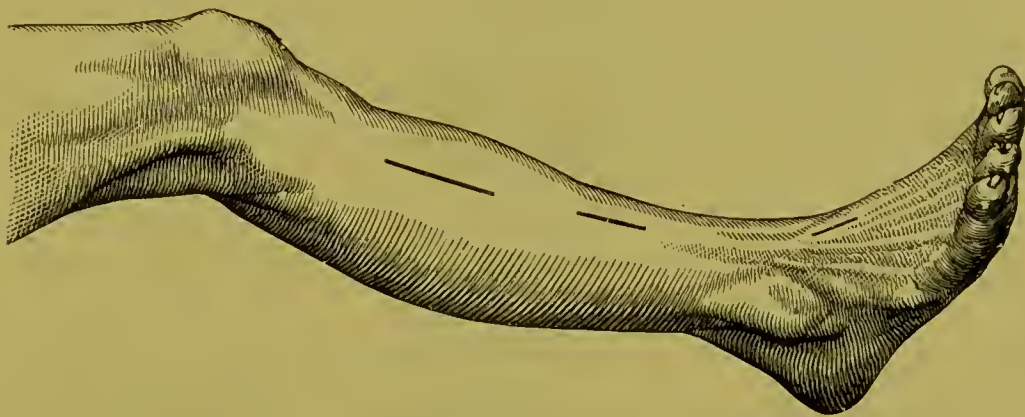

FIG. 80.—Position and general direction of the incisions which may be made to ligate the anterior tibial and dorsalis pedis arteries.

LIGATURE OF THE ANTERIOR TIBIAL ARTERY IN THE LOWER THIRD OF THE LEG.

Guide.—In the lower third of the leg, the line before indicated.

Operation.—Make an incision, two to three inches long (Fig. 80), through the skin and cellular tissue to the fascial aponeurosis. Seek the interval between the tibialis anticus and extensor proprius pollicis tendons. Divide the aponeurosis, and then the artery with its venæ comites, surrounded by fatty cellular tissue, will be exposed. Pass the needle from without inwards, taking care to exclude the nerve.

LIGATURE OF THE ANTERIOR TIBIAL ARTERY IN THE MIDDLE THIRD OF THE LEG.

Guide.—In the middle third of the leg, line already indicated, and the outer border of tibialis anticus muscle. This muscle, as a rule, can readily be called into action before the patient is anæsthetised, and being thus put into strong relief indicates the position of the inter-muscular septum.

Operation.—Make an incision, three and a half inches long (Fig. 80), about an inch external to the crest of the tibia, through the superficial parts to the deep fascia. Seek the whitish yellow line shining through the aponeurosis, which indicates the septum between the tibialis anticus on the inner, and the extensor longus digitorum muscle on the outer side (this will be more readily discovered at the lower extremity of the wound). Divide the aponeurosis longitudinally, and then, if more room be needed, transversely. If the transverse division be first made the intermuscular septum will sometimes be more readily discovered. Flex the foot. Separate the muscles carefully from below upwards. The nerve is first seen on the outer side or in front of the artery, which lies upon the interosseous membrane accompanied by venæ comites. It is not a matter of much moment whether the veins be, or be not, included in the ligature. They are often difficult to separate, but the nerve must be carefully excluded.

LIGATURE OF THE ANTERIOR TIBIAL ARTERY IN THE UPPER THIRD OF THE LEG.

The artery in the upper third of the leg is very deeply placed.

Operation.—A pre-existing wound will probably be the chief guide to the vessel. This should be enlarged in the direction of the interval between the tibialis anticus and extensor longus digitorum, and the bleeding points sought for and secured.

Collateral Circulation (Fig. 82).

<i>Anterior peroneal, malleolar branches</i>	with	{	<i>Malleolar branches of posterior tibial.</i>
			<i>Tarsal branch of dorsalis pedis.</i>
<i>Internal plantar</i>	with	{	<i>Dorsalis pedis (on inner side of foot).</i>
<i>External plantar, by communicating and perforating branches</i>	with		<i>Dorsalis pedis and its branches.</i>

LIGATURE OF THE POSTERIOR TIBIAL ARTERY.

Indications.—Wound, aneurism. This artery may be secured in any part of its course, usually on account of injury. Below it is superficial, above it is deeply placed beneath the gastrocnemius and soleus muscles. Behind

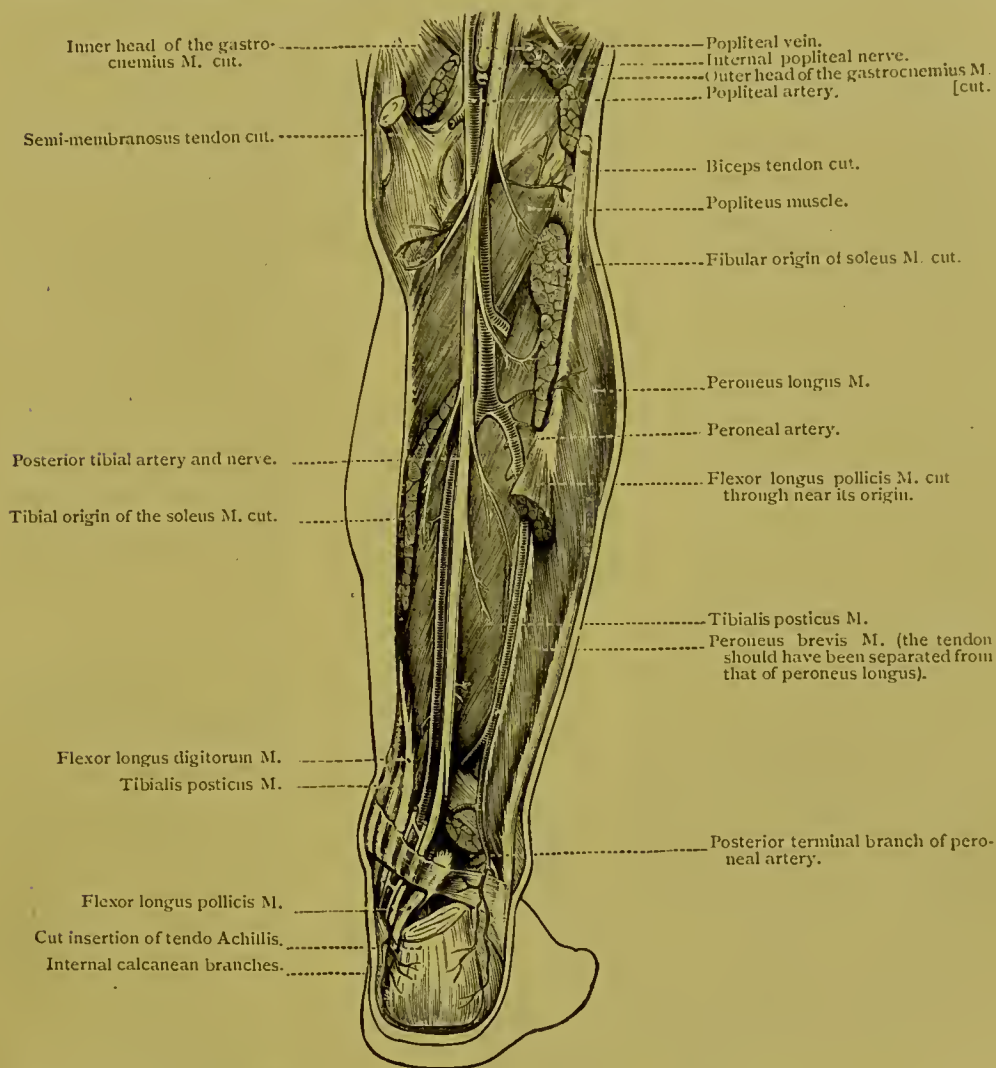


FIG. 81.—Anatomical relations of the posterior tibial and peroneal arteries.

the malleolus, or in the lower third, the vessel may require ligature for a wound of the sole of the foot, or of the artery itself near the ankle, such as is inflicted, for example, by a carpenter's adze.

Surgical Anatomy.—This artery is larger than the anterior tibial. It extends obliquely downwards and inwards from the inferior margin of the popliteus muscle to the fossa between the internal malleolus and os calcis (Figs. 81, 82). At its commencement it is crossed by the tendinous arch connecting the origins of the soleus muscle. The gastrocnemius and soleus muscles, and the plantaris tendon, cover the upper two-thirds of the artery. It lies upon the deep flexor muscles, and is invested by the deep posterior tibial fascia. In the lower third it descends along the inner border of the tendo Achillis and is covered, as it lies upon the tibia accompanied by its venæ comites, by the superficial fascia and two deep fascial layers. The nerve lies throughout close to the outer side.

Direction.—A line drawn from the middle of the ham to the midpoint between the tendo Achillis and internal malleolus.

LIGATURE OF THE POSTERIOR TIBIAL ARTERY IN THE LOWER THIRD OF THE LEG.

Surgical Anatomy.—The artery lies here between the flexor longus digitorum and longus pollicis tendons. It is covered by the internal annular ligament, accompanied by the nerve externally, and by two large venæ comites. It is enveloped in fatty cellular tissue.

Guide.—Line indicated.

Operation.—To secure the vessel in the lower third, an incision about two inches long may be made in the course of the artery, a finger's breadth behind the edge of the bone or halfway between the posterior margin of the tibia and the tendo Achillis. The incision should be slightly curved below (Fig. 88), and terminate about half an inch beneath the tip of the malleolus. Two layers of deep fascia require division, and a portion of the annular ligament. The artery will then be exposed with the nerve behind and external. Pass the needle from behind forwards. Avoid opening the fascial sheaths of the tendons (Fig. 81).

LIGATURE OF THE POSTERIOR TIBIAL ARTERY IN THE UPPER AND MIDDLE THIRDS OF THE LEG.

Surgical Anatomy.—The vessel lies, in its middle and upper third, covered by fascia, upon the deep layer of muscles. The muscles of the calf are superimposed. It is very deep in the upper part of its course.

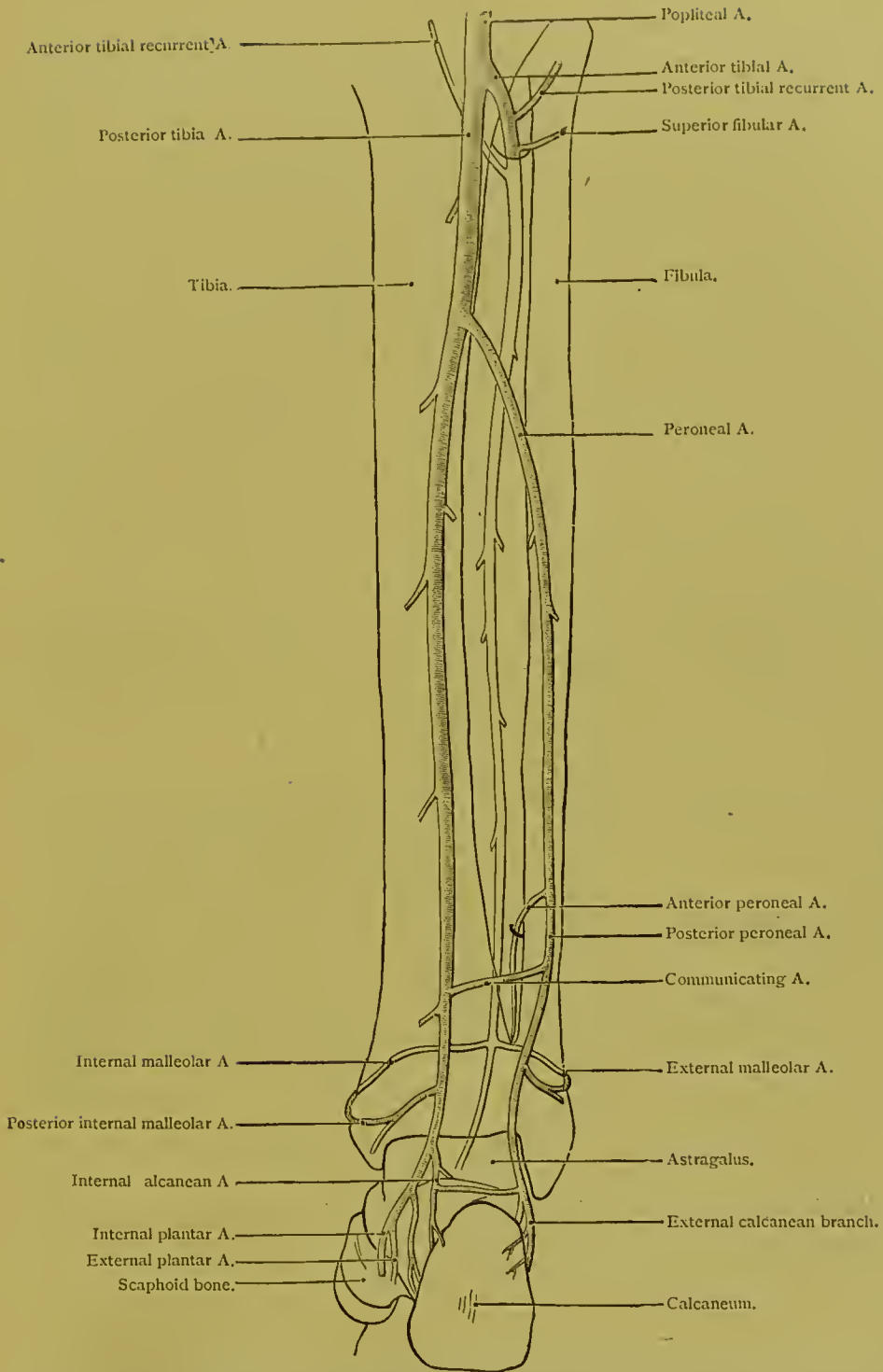


FIG. 82.—Diagram of the collateral branches and arterial communications in the leg and at the ankle.

Operation.—Lay the limb on its outer side, with the knee flexed and ankle extended. Make an incision about four inches long in the middle third of the leg (Fig. 88), three-quarters of an inch behind the inner border of the tibia. Take care to avoid the saphena vein. Expose and draw aside the border of the gastrocnemius, then divide the tibial origin of the soleus which is aponeurotic in its interior. As a rule, no muscular fibres are attached to the deep surface of the tendon for half an inch from its insertion. If the muscle be cut through at this point, the space in which the artery is to be found is at once opened. If the incision be made a little more external, there will be a further layer of muscular fibres to divide. Carefully expose and divide the intermuscular septum or deep fascia, covering the vessels. The nerve will first come into view. The artery may then be isolated and ligatured. The operation is easy on the dead subject, but would be far from simple on the living body.

This artery, as well as the peroneal artery, may be reached by the so-called "bloody operation," *i.e.* by cutting exactly in the median line through the calf muscles. The incision must then be at least six inches long.

Collateral Circulation (Fig. 82).

<i>Anterior tibial, internal malleolar branch</i>	} with {	<i>Posterior ^{internal} inferior malleolar of posterior tibial (Henle.)</i>
<i>Peroneal</i>		
<i>Communicating</i>	with	<i>Posterior tibial below ligature.</i>
<i>Muscular</i>	with	<i>Muscular of posterior tibial.</i>
<i>External calcanean (Henle)</i>	with {	<i>Calcanean branches of posterior tibial and external plantar.</i>

LIGATURE OF THE PERONEAL ARTERY.

Indications.—This operation will very rarely be required. For injury, however, it may have to be performed, and it is necessary to know the position in which to find the artery.

Surgical Anatomy.—The vessel is given off about one inch below the lower border of the popliteus muscle, and passes obliquely downwards and outwards towards the fibula, along which it descends. Somewhat

above the middle of the fibula the vessel enters the flexor longus pollicis. It is first covered by the soleus and deep fascia, and rests upon the tibialis posticus muscle. It then descends along the inner border of the fibula in a fibrous sheath between the bone and flexor longus pollicis.

Operation.—Ligature of the upper portion of peroneal artery should not be attempted except for injury. To reach it make the incision along the outer border of the gastrocnemius. The operation is otherwise similar to that for the posterior tibial artery. The median incision through the centre of the calf may be utilized to expose this vessel near its origin. The artery can be also secured in the middle third of the leg. It becomes so small near the malleolus that no occasion should there arise for its formal ligature.

LIGATURE OF THE POPLITEAL ARTERY.

Indications.—Except to seek for a wound of the artery, or possibly for a small recent traumatic aneurism, this operation is not likely to be undertaken. The methods of Antyllus and Anel, formerly so commonly applied in this situation for popliteal aneurism, are altogether abandoned. Either operation was exceedingly difficult. Severe hæmorrhage and a very extensive wound were inevitable at the time, and these were apt to be followed by excessive suppuration, occasional implication of the knee-joint, frequent gangrene and secondary bleeding. Rather than face these risks, most surgeons preferred to amputate the limb.

Surgical Anatomy.—The vessel, about six inches in length, extends from the opening in the adductor magnus muscle to the lower border of the popliteus. It is covered by skin, superficial and popliteal fascia, and much fatty areolar tissue, and overlapped above by the semi-membranosus muscle. The vein is closely adherent to its superficial surface, projecting externally above, and to the inner side below, the internal popliteal nerve is superficial to both. In the centre of the ham the nerve and vein will lie exactly over the artery. In the lower part of the popliteal space the nerve is somewhat to the inner side of the vessel, above it is external (Fig. 83).

Direction.—The position corresponds with that of a line which runs somewhat obliquely from about three-quarters of an inch to the inner side of the middle line of the popliteal space above, to a point corresponding with the middle of the posterior surface of the limb below.

Operation.—The artery is most easily secured at the lower part of its course. Make a vertical incision in the centre of the ham, three inches long, exactly between the heads of the gastrocnemius. After dividing the skin, superficial fascia and fat, draw the short saphenous nerve and vein out of the way. Retract the popliteal nerve and vein to the outer side. Introduce the aneurism needle very carefully with its convexity towards the vein and nerve.

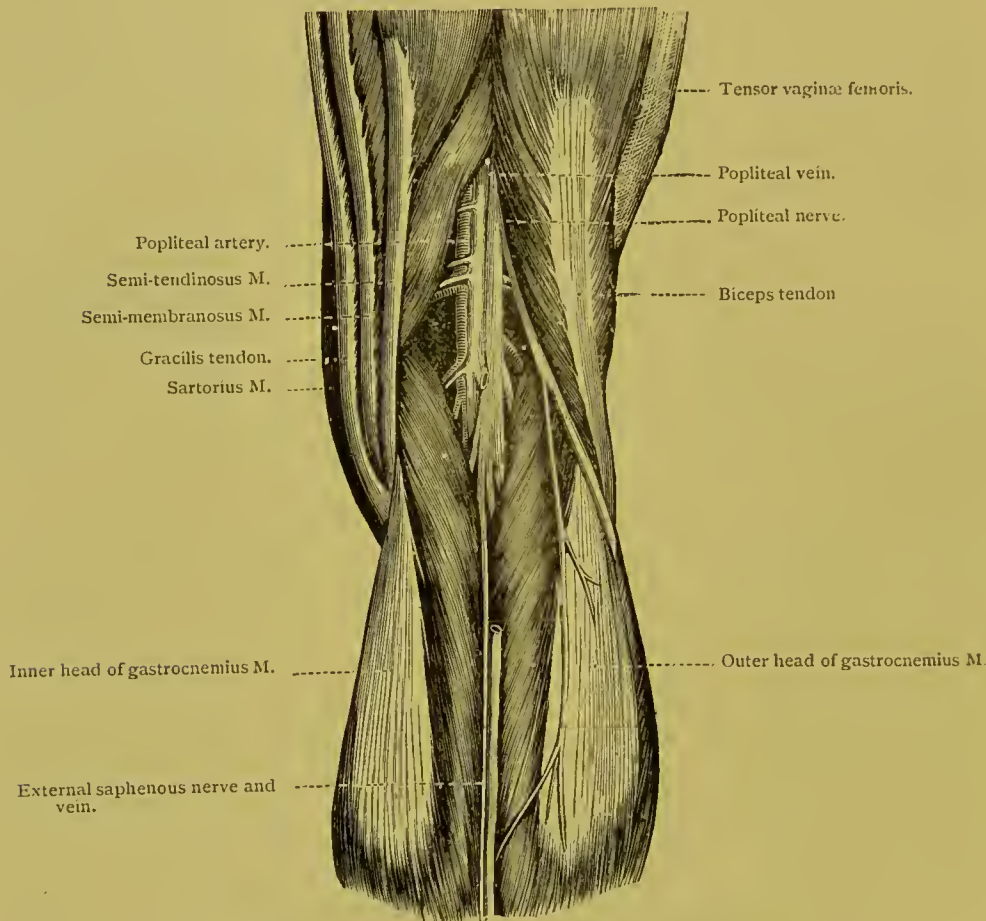


FIG. 83.—Anatomical relations of the right popliteal artery.

In order to tie the upper portion of the popliteal artery, flex the knee, and place the limb on the outer side. Make an incision three inches long immediately behind and parallel to the tendon of the adductor magnus muscle downwards from the junction of the middle and lower thirds of the thigh. Divide the skin, superficial and deep fascia,

avoid the long saphenous nerve, seek the tendon of the adductor magnus, draw it forwards, and the ham-string tendons backwards. The artery will then be found surrounded by fatty areolar tissue. The nerve and vein do not necessarily come into view, being on the external aspect of the vessel.

LIGATURE OF THE FEMORAL ARTERY.

Indications.—Popliteal aneurism. Femoral aneurism in the lower half of the thigh. Wounds of the artery or of any of its main branches. The femoral vessels in the groin are much exposed to injury, and the bleeding which may occur, either from the main trunk or one of its principal branches, like the profunda or perforating arteries, is very serious. Punctured wounds often occasion great difficulty in diagnosing the source of the hæmorrhage. The anatomical position of the wound affords no great assurance as to the exact point of the bleeding. John Hunter, in 1785, was the first surgeon in this country to place a ligature on the femoral artery for popliteal aneurism, and he did so at that part of the vessel which lies in the fibro-muscular canal which subsequently has borne his name. The first to follow Hunter's example was Mr. Birch, of St. Thomas's Hospital, who tied the femoral artery for aneurism in a negro called Lewis. Desault in the same year applied a ligature to the artery on the proximal side of a popliteal aneurism. The part of the vessel tied seems to have been the upper end of the popliteal. The sac suppurated, but the patient recovered notwithstanding. The artery has been tied for the cure of elephantiasis arabum, and as a means of arresting acute inflammation in the knee-joint, as carried out by Maunder at the suggestion of Little.

Carnochan, in 1851, adopted this method of treatment for elephantiasis arabum, and it has since been frequently resorted to. The results are uncertain, and the disease in most cases was influenced only in a very temporary degree.

The hope of arresting the progress of a new growth, which has frequently led to the ligature of the carotid artery and its branches in the neck, finds no parallel indication in the lower extremity. Amputation is performed instead.

The femoral artery and femoral vein have also been wounded, or in part excised, during the removal of tumours of the thigh, and double ligatures must in that case be applied.

Surgical Anatomy.—At first anterior to the femur, the artery soon becomes internal, and finally, as the popliteal artery, passes behind the bone. For a short distance beneath Poupart's ligament the femoral vein is internal to the artery, opposite the origin of the profunda the vein begins to become posterior, in the mid-thigh it is behind, and lower down it projects a little to the outer side of the vessel.

Below Poupart's ligament an infundibuliform prolongation of the fascia transversalis in front, and the iliac fascia behind, form a wide investing sheath for the artery and vein. This sheath is continuous below with the proper sheath of the vessels, and is divided by a septum which passes between the artery and vein.

At Poupart's ligament the anterior crural nerve, lying in the groove between the iliacus and the psoas muscles, is about a quarter of an inch external to the vessel. A large branch of the crural nerve, the internal saphenous, lies superficial and external to the artery in Hunter's canal. A smaller branch descends on the outer side of the artery, leaving it near the middle of the thigh to enter the vastus internus muscle.

The point at which the profunda artery is given off is of surgical importance. This vessel arises from the posterior external surface of the femoral artery, an inch and a half or two inches below Poupart's ligament. Sometimes it is given off considerably lower, or it may be higher. It passes downwards and slightly outwards upon the psoas tendon and upper part of the crureus, and then curves inwards behind the femoral artery, separated from it by the profunda and femoral veins and a quantity of areolar tissue.

The femoral artery may be tied either before it gives off the profunda, at the apex of Scarpa's triangle, or in Hunter's canal. Above the middle of the thigh seek for the vessel from the inner side of the sartorius muscle, while below the middle it is best to seek it from the outer side, where it will be found lying in the depression between the vastus internus and adductor muscles (Figs. 86, 87).

Direction.—A line drawn from the mid-point between the pubic symphysis and the anterior superior spine to the posterior margin of the internal condyle of the femur corresponds to the course of the vessel.

LIGATURE OF THE SUPERFICIAL FEMORAL ARTERY IN HUNTER'S CANAL.

Surgical Anatomy.—Hunter's canal—the second surgical situation of the artery—corresponds to the middle third of the thigh, and is about four inches in length (Fig. 87). The strong aponeurosis connecting the vastus internus and adductor longus and magnus muscles, which helps to form Hunter's canal, gradually commences underneath the apex of Scarpa's triangle, and terminates abruptly opposite the opening in the adductor magnus muscle through which the vessels pass to become popliteal, a point a little less than four inches above the upper border of the patella, and corresponding to the junction of the middle with the lower thirds of the thigh. Within Hunter's canal the artery and vein lie in their sheath. Somewhat anterior and external to it are two branches of the crural nerve, the long saphenous nerve lying within Hunter's canal, and a branch to the vastus internus lying superficial to the canal.

Guide, in Hunter's canal.—Line already indicated. The artery is covered by the sartorius, and the deep aponeurosis.

Operation.—Seldom performed. Flex, abduct, and rotate the thigh outwards; flex the leg. Make an incision three and a half inches long (Fig. 88), in the middle third of the thigh, through the skin and fascia, carefully avoiding the saphena vein. The sartorius will now be recognized; draw this muscle either outward or inward, preferably the latter. Lay open Hunter's canal, and afterwards open the vascular sheath, taking care to avoid the long saphenous nerve. The femoral vein lies behind or slightly external, and is very closely connected with the artery. To avoid injuring it the needle must be very cautiously introduced either from the inner or outer side.

LIGATURE OF THE SUPERFICIAL FEMORAL ARTERY AT THE SEAT OF ELECTION.

Surgical Anatomy.—Scarpa's triangle is the most important surgical situation of the artery. It corresponds to the upper third of the thigh.

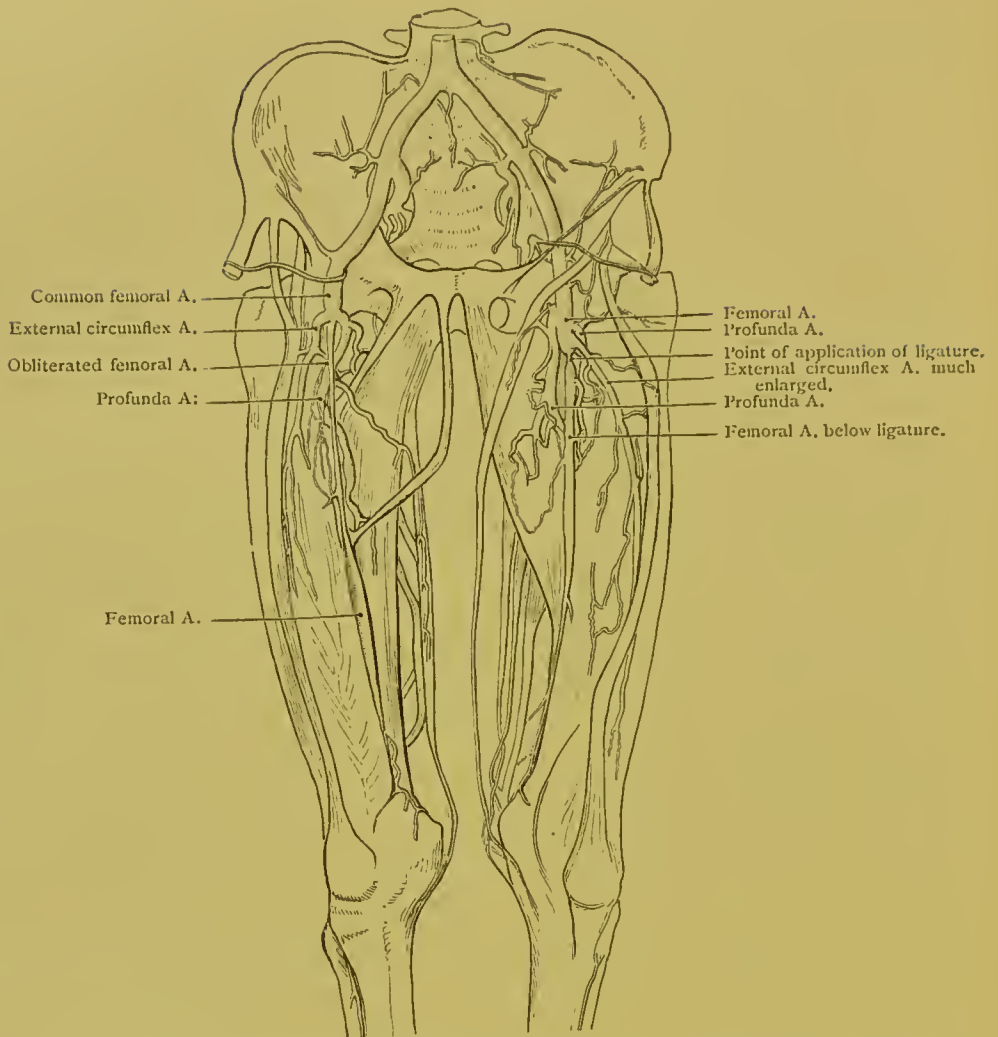


FIG. 84.—Drawing from a dried specimen (anterior view). Both femoral arteries have been ligatured for double popliteal aneurism. An abundant collateral circulation has been established.

The drawings are made from a dried preparation which had previously been carefully dissected and injected. Both femoral vessels have been tied and an abundant collateral circulation is established. Mr. Todd, of the Richmond Hospital, tied the left superficial femoral artery in 1817, the patient being then twenty-nine, and the right, three years later, for popliteal aneurism in both instances. The man died in 1836. On the right side the vessel has been tied five inches below Poupart's ligament, and two and three-quarter inches below the origin of the profunda, which is much increased in size, and gives off a very large branch to the short adductors. The perforating arteries are much enlarged. A large branch of the middle perforating communicates directly with a muscular branch of the femoral given off in Hunter's canal. In the popliteal spaces the artery is represented by a fibrous cord. On the left

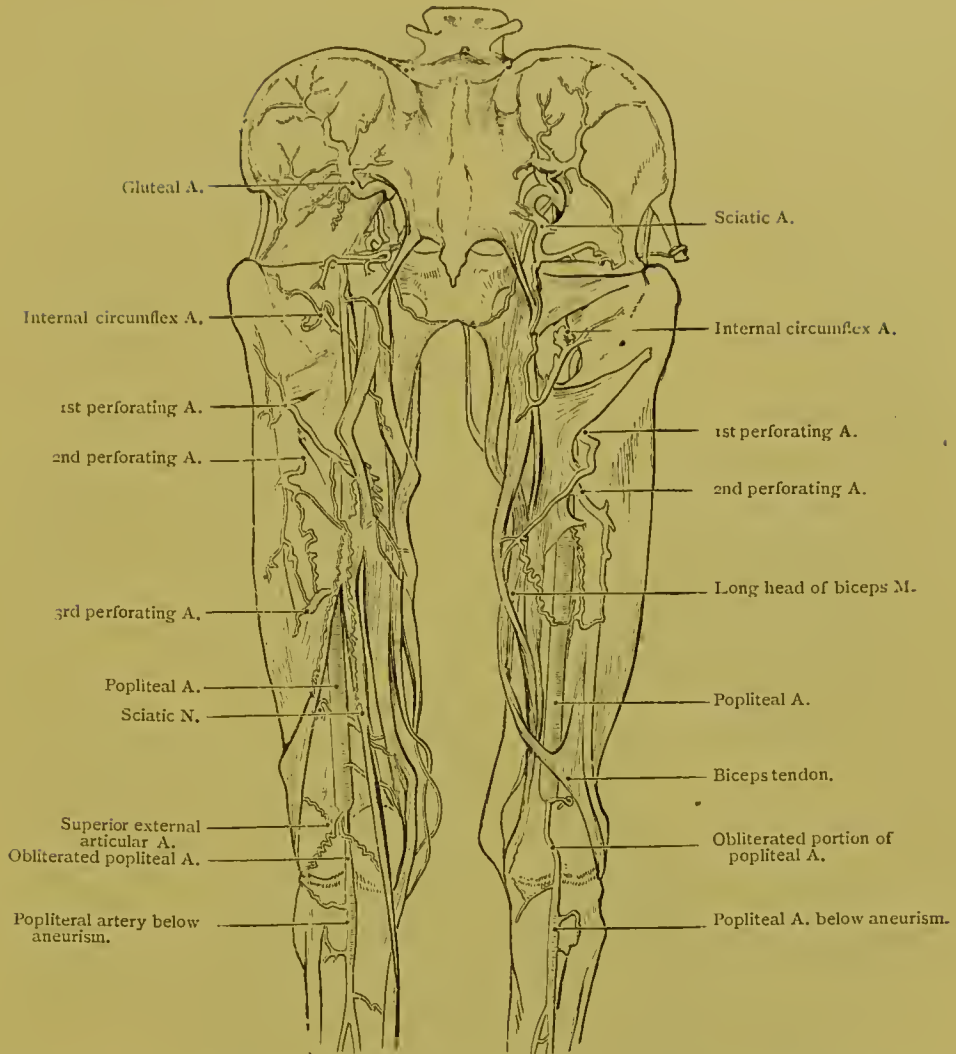


FIG. 85.—Drawing from a dried preparation, showing the enlargement of the anastomotic circulation after ligation of the femoral artery on both sides (posterior view). The specimen is preserved in the Richmond Hospital Museum, Dublin.

side two superior external articular arteries anastomose with the inferior external articular.

The left femoral artery was tied three and a half inches beneath Poupart's ligament and one and a half inches below the profunda. Three-quarters of an inch below the point of ligation a branch as big as the radial at its origin passes into the adductor magnus, and communicates with perforating branches of the profunda. The profunda itself gives off, as on the other side, a very large branch to the short adductors.

Branches from the right and left internal circumflex anastomose with the sciatic.

The gluteal and sciatic arteries are much enlarged. They communicate with enlarged branches of the external and internal circumflex, and the superior perforating arteries on the back of the limb.

The artery passes through this space from the centre of the base at Poupart's ligament to the apex or angle formed by the crossing of the sartorius over the adductor longus muscle. The apex of the triangle, the position near which the artery is most frequently ligatured, is a hand's breadth, or four inches, below Poupart's ligament. As in some cases the profunda is given off as low as four inches, it has been recommended to tie the artery a little lower than the point indicated. The artery is here comparatively superficial, but it will be more or less covered by the sartorius according to the muscularity of the subject (Figs. 86, 87).

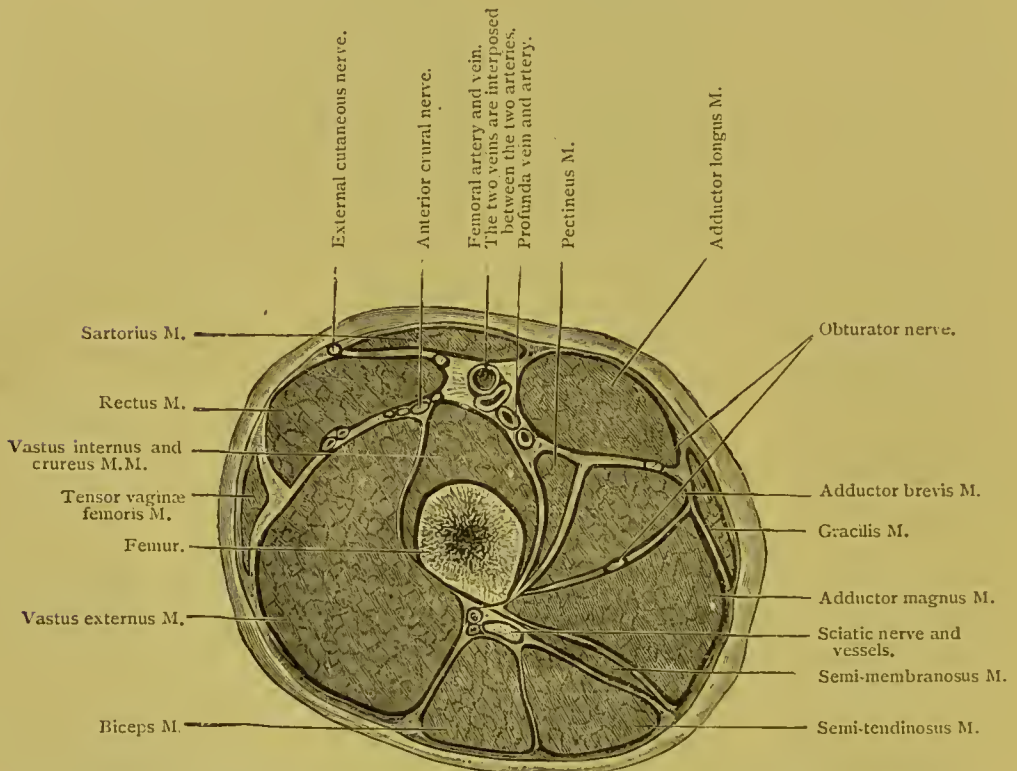
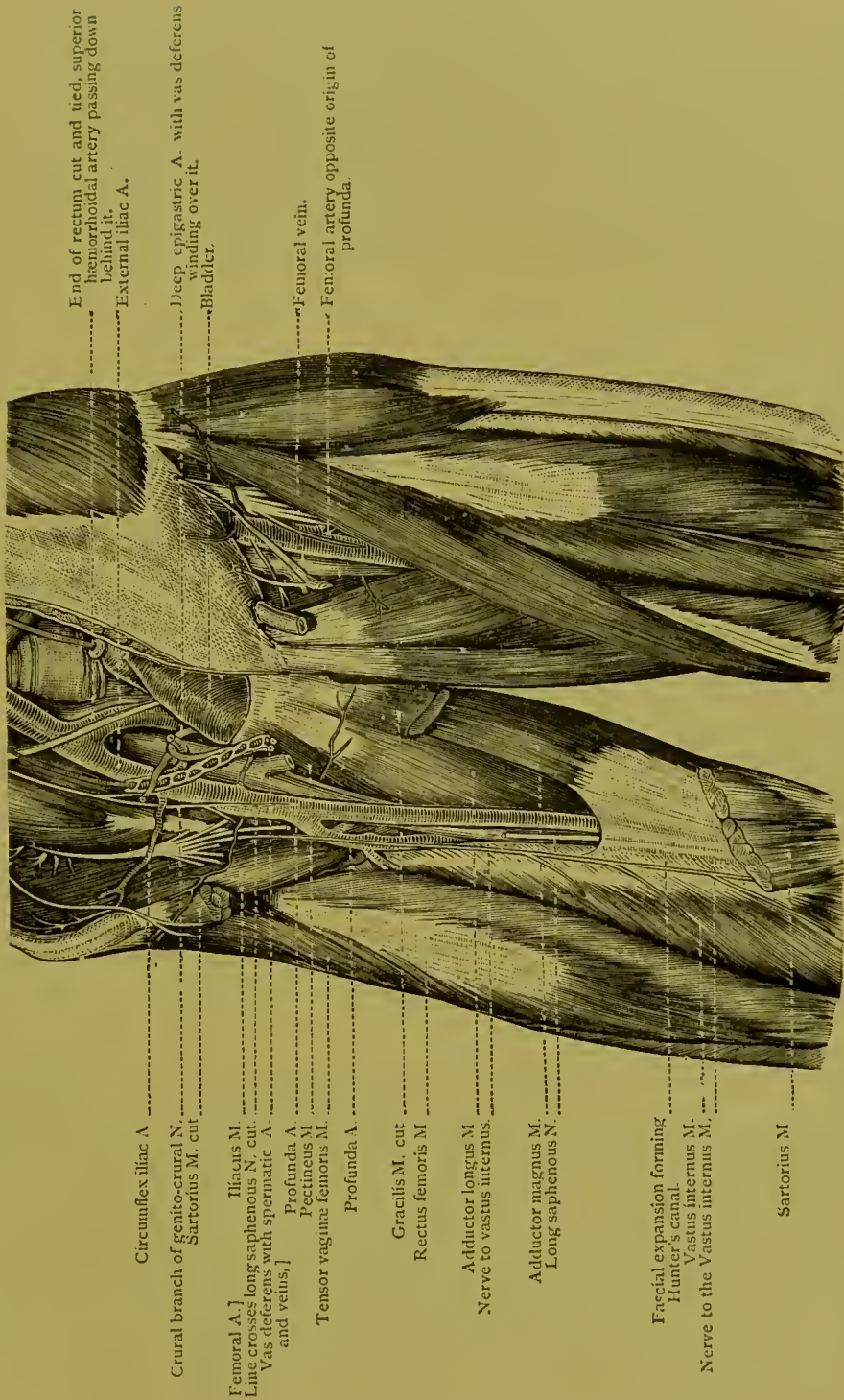


FIG. 86.—Transverse section of the right thigh at the apex of Scarpa's triangle.

Operation.—Ligature of the superficial femoral, near the apex of Scarpa's triangle is the proceeding generally adopted. The hip having been slightly flexed and the thigh everted, the artery will easily be reached by an incision, three inches long, in the line of the vessel (Fig. 88). Its centre



End of rectum cut and tied, superior hemorrhoidal artery passing down behind it.
 External iliac A.
 Deep epigastric A. with vas deferens winding over it.
 Bladder.
 Femoral vein.
 Femoral artery opposite origin of profunda.

Circumflex iliac A.
 Crural branch of genito-crural N.
 Sartorius M. cut
 Femoral A.]
 Iliacus M.
 Line crosses long saphenous N. cut.
 Vas deferens with spermatic A.
 and vein,]
 Profunda A.
 Pectineus M.
 Tensor vaginae femoris M.
 Profunda A.
 Gracilis M. cut
 Rectus femoris M.
 Adductor longus M.
 Nerve to vastus internus.
 Adductor magnus M.
 Long saphenous N.
 Fascial expansion forming Hunter's canal.
 Vastus internus M.
 Nerve to the Vastus internus M.
 Sartorius M

FIG. 87.—Surgical anatomy of the iliac and femoral arteries.

should correspond to the apex of the triangle, and in this position the ligature ought to be applied. Ascertain the position of the internal saphena vein, and avoid it. After dividing the skin, fascia, and fat, seek the inner border of the sartorius, and draw the muscle outwards. Avoid the crural branch of the genito-crural nerve, the internal cutaneous and long saphenous nerves, and the nerve to the vastus internus, which follow the line of the artery. Open the sheath of the vessel towards the outer side, and

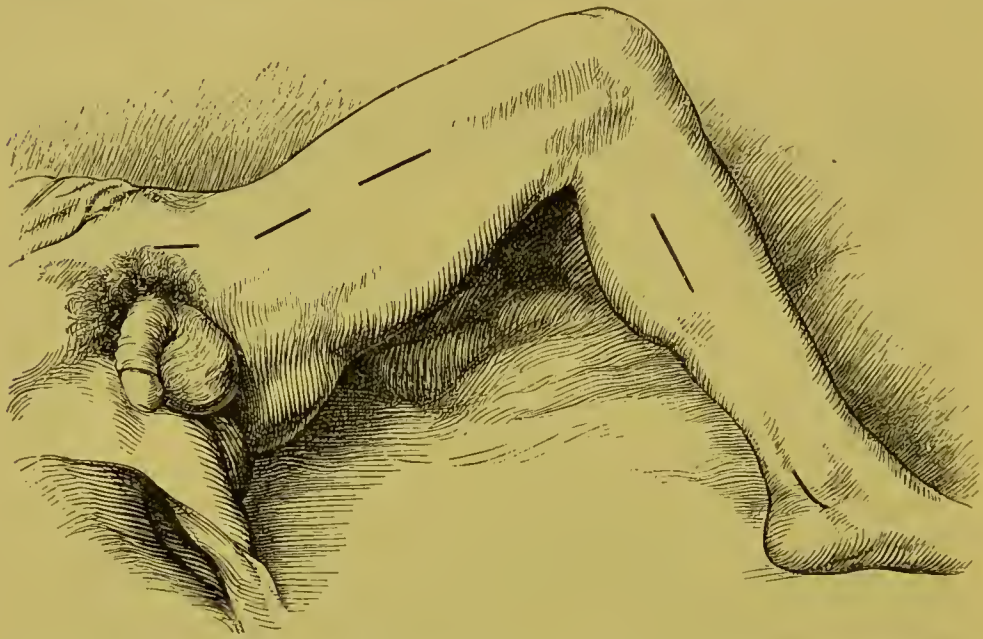


FIG. 88.—The lines indicate the incisions to be made for the ligature of the common femoral artery, the superficial femoral, the femoral in Hunter's canal, and ligature of the posterior tibial artery in the calf and behind the malleolus.

thoroughly expose it by teasing through its proper sheath. This is the best way to ensure safety for the vein. The femoral vein lies behind and somewhat internal. The anterior crural nerve is on the outer side. Pass the needle from the inner side. The vein has occasionally been wounded in passing the aneurism needle, and even some of the before-mentioned nerves included. The operation is perhaps the most successful of any for ligature of a large artery. Gangrene of the limb is the after-accident most to be apprehended.

LIGATURE OF THE COMMON FEMORAL ARTERY.

Indications.—Wound, aneurism. Ligature of the common femoral artery near Poupart's ligament and above the origin of the profunda is easy. The artery is comparatively superficial, but the operation is by no means a successful one. Secondary hæmorrhage and gangrene of the limb seem to have very frequently followed it. It appears to be more dangerous to tie the vessel between the origin of the deep epigastric and the giving off of the profunda, than at either above or below these points.

Surgical Anatomy.—The vessel extends from Poupart's ligament to the origin of the profunda. Its usual length is one inch and a half. It is quite superficial, being covered only by the skin, subcutaneous areolar tissue and fat, superficial and deep fasciæ and lymphatic glands. The vein is internal, and when full overlaps the artery. The anterior crural nerve is outside the sheath of the vessel, and a quarter of an inch distant.

Guide.—Line already indicated.

Operation.—Make an incision, two inches long, over the course of the vessel, commencing just over Poupart's ligament (Fig. 88). Divide the skin and superficial fascia, avoiding the lymphatic glands and saphena vein. Cut through the cribriform fascia and fascia lata, and carefully isolate the artery close to Poupart's ligament. Pass the aneurism needle from within outwards. Avoid including the crural branch of the genito-crural nerve, which lies on the sheath of the artery. Tie the artery as far as possible from the variable origin of the profunda. The vein lies immediately internal, but separated from the artery by a septum in the sheath. The distance at which the profunda is given off is, as a rule, one inch and a half below Poupart's ligament, but it may be one inch only, or, in some cases, quite at the level of the ligament. The deep epigastric and deep circumflex iliac arteries sometimes arise below Poupart's ligament, the usual position being immediately above. Some surgeons have preferred to expose the vessel by an incision parallel to and just below Poupart's ligament, but this possesses no apparent advantage over an incision in the direction of the artery.

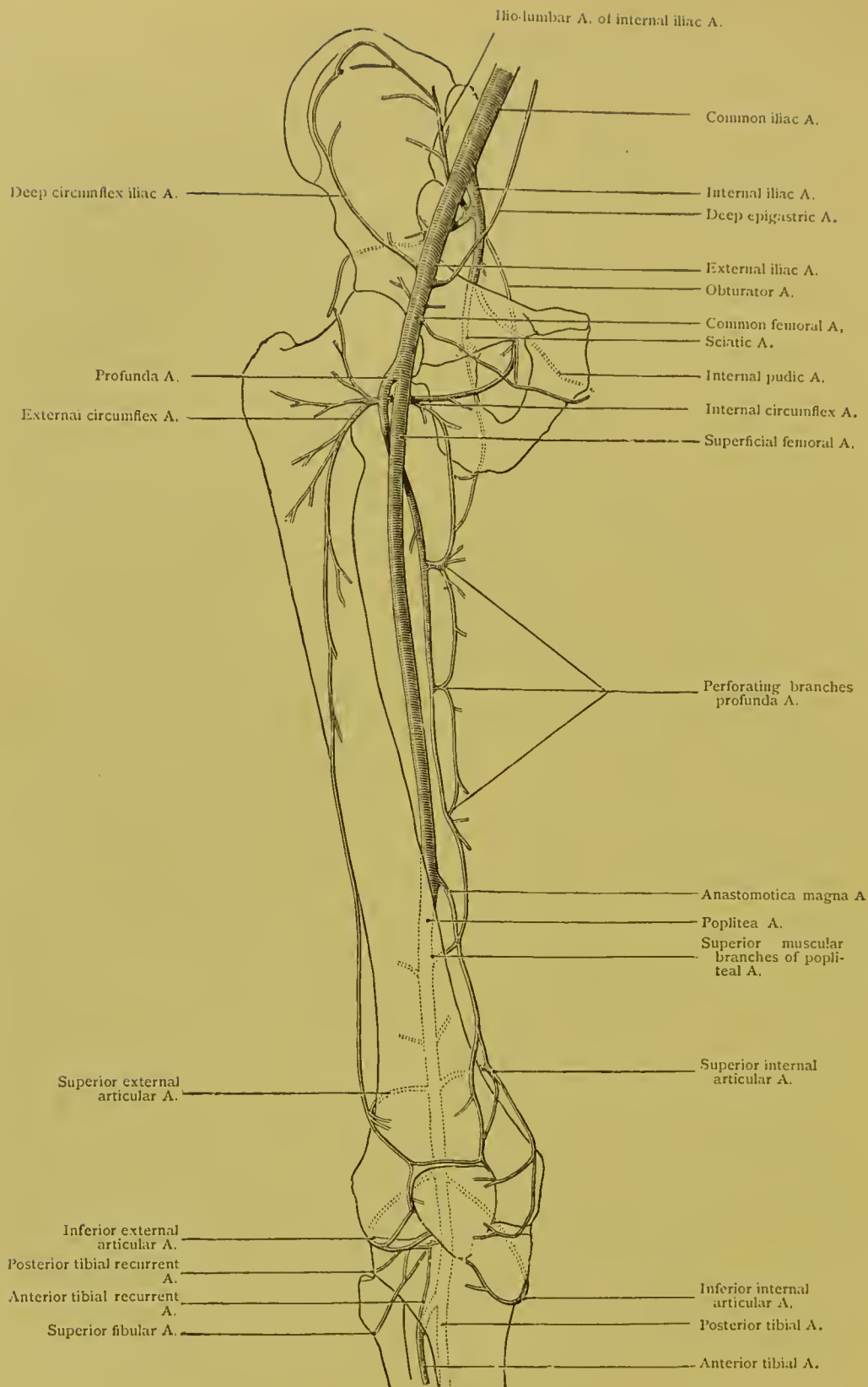


FIG. 89.—Anastomotic circulation of the iliac and femoral arteries.

Professor Rawdon Macnamara, however, attaches importance to the direction of the wound, and in 1867 published an account of eight cases operated on by the transverse incision. In six a successful result followed.

Collateral Circulation (Fig 89).

Above the Profunda—

CARDIAC SIDE.	DISTAL SIDE.
<i>Gluteal</i>	with { Branches of external and internal circumflex.
<i>Superficial circumflex iliac</i>	with { Ascending of external circumflex.
<i>Obturator (by branches external to pelvis)</i>	} with Internal circumflex.
<i>Sciatic</i>	with { Superior perforating and internal and external circumflex.

Below the Profunda—

<i>Descending branches of external circumflex</i>	} with { Lower muscular branches of femoral. Superior articular of popliteal, anastomotica magna.
<i>Perforating and terminal branches of profunda</i>	} with { Muscular branches of femoral below ligature, and of popliteal, superior articular.
<i>Sciatic by comes nervi ischiadici</i>	with { Small branches from femoral, popliteal, and posterior tibial arteries.

LIGATURE OF THE EXTERNAL ILIAC ARTERY.

Indications. — Wounds, secondary hæmorrhage, femoral aneurism, more especially in the upper half of the thigh. Abernethy was the first to perform the operation in 1796. It is in fact one of the most successful of the ligatures of large arteries, the mortality heretofore being but slightly in excess of that after the ligature of the superficial femoral. Before the introduction of antiseptic methods, diffuse inflammation of the pelvic cellular tissue was liable to complicate the operation. Peritonitis also sometimes followed, even when the peritoneal sac was unwounded.

Occasionally the external iliac artery has been tied for aneurism of the aorta or common iliac, after the method suggested by Brasdor. But the distal operation has proved very unsuccessful when practised on the arteries of the lower half of the body. Secondary hæmorrhage, gangrene, and bursting of the sac have been the most usual consequences.

Surgical Anatomy.—The artery is about four inches long, and lies, covered by a thin fascia, on the inner border of the psoas, with its vein internal (Fig. 87). The genital branch of the genito-crural nerve lies upon it. The spermatic vessels and circumflexa ilii vein cross it near Poupart's ligament. The vas deferens joins the spermatic vessels on the inner side of the artery near its termination. The deep epigastric and circumflex iliac arteries are given off from it close to Poupart's ligament. The ureter usually crosses the bifurcation of the common iliac.

Direction of vessel.—This corresponds to the lower two-thirds of a line drawn from a point three-quarters of an inch below and to the left of the umbilicus to the midpoint between the anterior superior spine of the ilium and pubic symphysis (Fig. 92).

Operation.—The bowels ought to be previously well cleared out. The operation will be facilitated by elevation of the pelvis. Make a curvilinear incision, the convexity being outward and downward, parallel to Poupart's ligament and in the direction of the fibres of the external oblique aponeurosis (Fig. 92). It should be three to four inches long, and extend from about half an inch above the centre of Poupart's ligament to a point an inch above, and internal to, the anterior superior spine. The deeper portions of this incision will always be external to the internal abdominal ring and the epigastric artery. Divide the skin, subcutaneous fat, and external oblique aponeurosis on a director, and then the fibres of the internal oblique and transversalis muscles, thus exposing the transversalis fascia. Divide this very carefully, to a limited extent, beginning at the lower angle of the wound. Introduce a finger into the subperitoneal areolar tissue, and displace the peritoneum gently upwards and inwards, as far as the inner border of the psoas muscle. It requires to be disturbed but little, except for the upper portion of the artery. The higher the ligature needs to be applied to the vessel, the higher up and the more internal must the upper limit of the incision be prolonged. It is of importance not to divide the muscles of the abdomen

too freely, as a hernial protrusion is liable to occur at the cicatrix. This tendency may be obviated in some cases by carefully suturing the divided margins of the aponeurosis. Before attempting to pass the ligature, it is necessary to divide, with some blunt instrument, the layer of subperitoneal tissue which binds the vessel down to the iliac fascia. Pass the needle from within outwards. It is not advisable to tie the artery too near its commencement or termination. The place to select is generally the middle, which is about an inch and a half above Poupart's ligament.

If the vessel require to be ligatured near its termination, it may be readily reached by a gently curved incision, about three inches long, following the line of Poupart's ligament, and rather less than half an inch above it. The internal extremity of the incision will be a little external to the external abdominal ring. After the superficial structures have been cut, only the aponeurosis of the external oblique need be divided. In doing so, the outer portion of the inguinal canal is laid open below the spermatic cord. The inferior margins of the two other muscles may be readily displaced upwards along with the spermatic cord. The transversalis fascia can be easily torn through with a director. The artery will be found at the inner border of the psoas muscle, surrounded by fat and lymphatic glands, and the needle should be passed round it from within outwards. In this operation the ligature will have to be applied in somewhat close proximity to the deep epigastric and circumflex iliac arteries.

Secondary hæmorrhage and gangrene have been the most frequent causes of death.

Collateral Circulation (Fig 89).

<i>Ilio-lumbar of internal iliac</i>	with	<i>Deep circumflex iliac.</i>
<i>Gluteal</i>	with	{ <i>Circumflex iliac.</i> <i>External circumflex.</i> <i>Internal circumflex.</i>
<i>Obturator, by pubic branch</i>	with	<i>Pubic branch of epigastric.</i>
<i>by branches external to pelvis</i>	with	<i>Branches of internal circumflex.</i>
<i>Sciatic artery by muscular branches</i>	with	{ <i>Internal and external circumflex.</i>
<i>and comes nervi ischiadici</i>	with	<i>Perforating branches of profunda.</i>
<i>Internal pudic</i>	with	<i>External pudic.</i>
<i>Internal mammary</i>	with	<i>Deep epigastric.</i>

LIGATURE OF THE INTERNAL ILIAC ARTERY.

Indications.—The artery may require ligature for hæmorrhage from its branches, and for aneurism, more especially gluteal. This vessel has been ligated eleven times for gluteal aneurism. In five instances a favourable result followed. Stevens of Santa Cruz first tied the artery, in 1812, with complete success. Several years after, on the patient's death, the specimen was secured, and presented to the museum of the Royal College of Surgeons. All the operations performed on account of hæmorrhage terminated fatally.

Anatomical relations.—The artery is about an inch and a half long, and runs from the bifurcation of the common iliac to the upper margin of the great sciatic notch, or along the border of the sacrum in a nearly vertical direction. It lies upon the internal iliac vein, with which it is in close relation, and the lumbo-sacral nerve.

Operation.—The external wound made to secure the internal iliac artery is similar to that for ligature of the termination of the common iliac. After the superficial structures are divided and the peritoneum displaced inwards, the external iliac will be first met with, and should be traced to its origin. The position of the internal iliac can then be made out. It is very difficult to pass the aneurism needle round it. Both the external and internal iliac veins are in close relationship with it. When the artery is short it is deeply seated in the pelvis and difficult to reach, and in this case it may be better to tie the common iliac.

Collateral Circulation (Fig. 89).

<i>Sciatic</i>	with	<i>Superior branches of profunda.</i>
<i>Hæmorrhoidal branches</i>	with	<i>Branches of inferior mesenteric.</i>
<i>Pubic branch of obturator</i>	with	<i>Vessel of the opposite side.</i>
<i>Circumflex, and perforating branches of the profunda</i>	} with {	<i>Sciatic, gluteal, and posterior sacral.</i>
<i>Lateral sacral</i>		
<i>Circumflex iliac</i>	with	<i>Ilio-lumbar of gluteal.</i>

GLUTEAL, SCIATIC, AND INTERNAL PUDIC ARTERIES.

Indications for Ligature.—Punctured and gunshot wounds may involve the gluteal, sciatic, or internal pudic arteries. Wounds and aneurisms of these deeply seated vessels are dealt with either at the point of injury and disease, or by the application of a ligature to the internal or common iliac artery. The latter proceeding is, however, so dangerous that in cases of injury, at all events, every attempt should be made to secure the bleeding vessel by a double ligature above and below the wound. I have been obliged to ligature the gluteal artery in a case in which severe hæmorrhage took place after opening an abscess of the buttock. Where the disease is aneurismal the method of Antyllus, laying open the sac and securing the artery as it enters and leaves it, may sometimes be adopted. This was the plan advocated by John Bell, Sir Charles Bell, and afterwards Mr. Syme. It is applicable to instances of aneurism of traumatic origin, which are by far the more common in this situation, but scarcely to idiopathic cases, or those in which the tumour involves the artery within the pelvis. In a muscular subject a very extensive wound has to be made in order to expose the deeper structures, but this is preferable to applying a ligature to the internal or common iliac arteries within the abdomen.

It is very important and often very difficult to determine the exact source of hæmorrhage in a given case, whether it be from the gluteal, sciatic, or pudic arteries, and similarly it may be difficult to localize an aneurism. Gluteal aneurism is, however, certainly four times as frequent as sciatic.

A pulsating tumour, or hæmorrhage from a wound near the upper border of the gluteus maximus is probably connected with the gluteal artery. Nearer the lower part the sciatic or pudic artery is more probably involved.

LIGATURE OF THE GLUTEAL ARTERY.

Surgical Anatomy.—The gluteal artery (Fig. 90) is the largest branch of the internal iliac; it emerges from the pelvis through the upper part of the sciatic notch, above the pyriformis muscle. It divides immediately into branches for the supply of the glutei muscles, is accompanied by two veins and covered, for the greater portion of its course, by the gluteus

maximus and medius muscles. The superior gluteal nerve passes out of the pelvis with the artery. Just as it comes through the notch a small portion of the vessel lies uncovered by the gluteus medius, so that at this point it may be reached after simply dividing the gluteus maximus muscle.

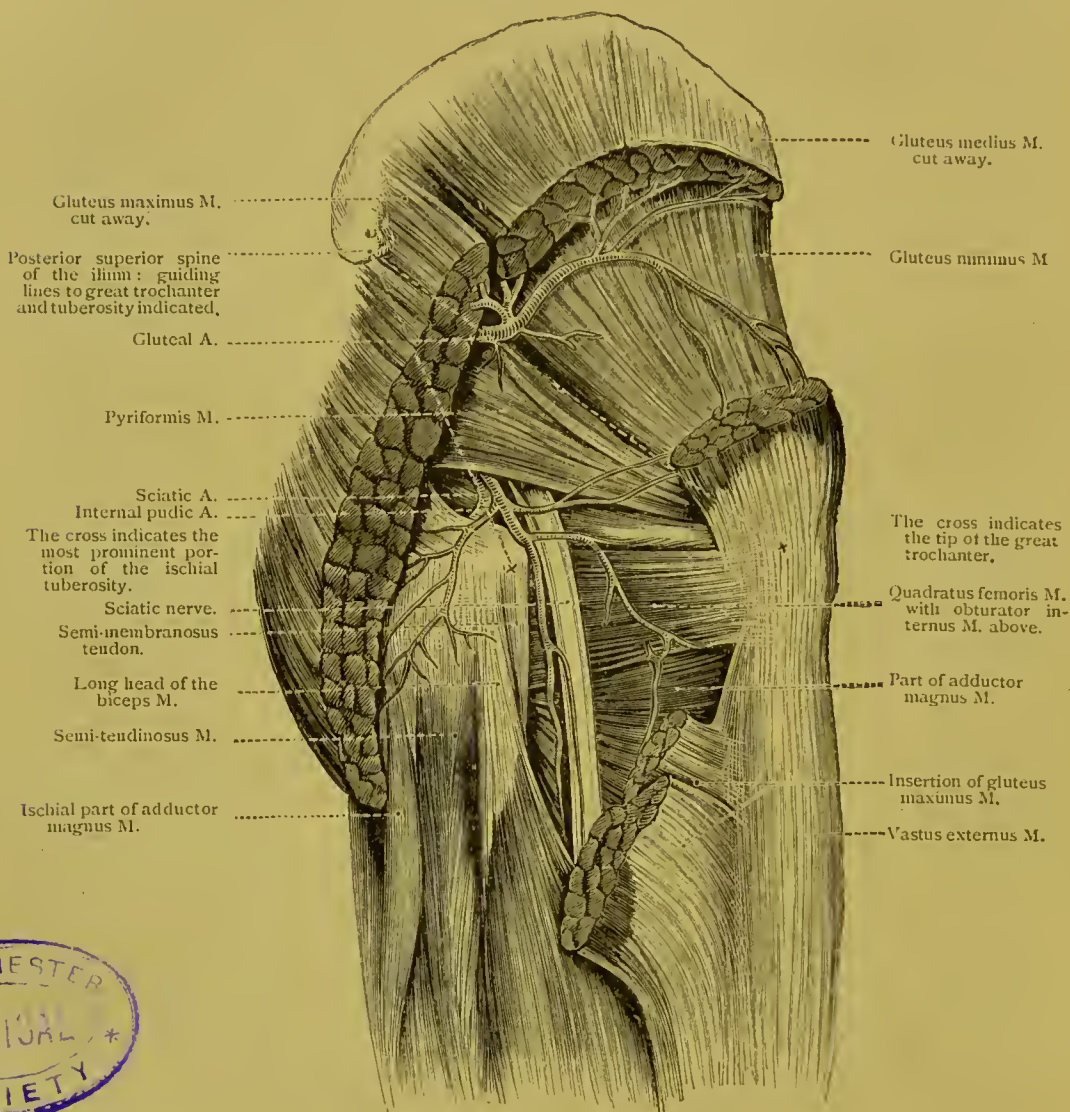


FIG. 90.—Surgical anatomy of the gluteal, internal pudic, and sciatic arteries.

Direction.—If a line (Fig. 91, A B) be drawn from the posterior superior spine to the great trochanter, the limb being slightly flexed and rotated inwards, the point of emergence of the gluteal artery from the upper part

of the sciatic notch will correspond to the junction of the upper with the middle third of this line.

Operation.—To reach the gluteal artery, an incision, four or five inches long, should be made in the direction of a line running from the tip of the

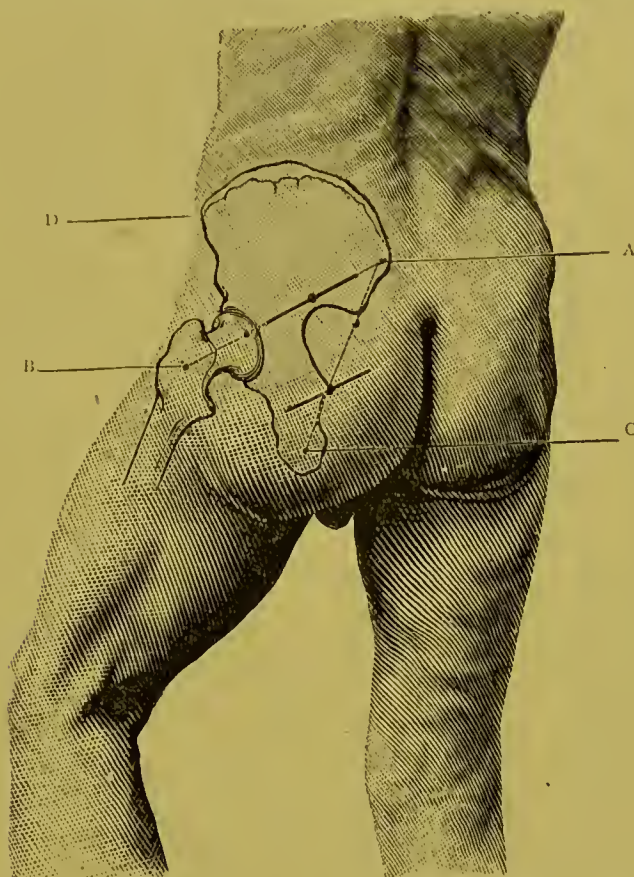


FIG. 91.—Position and direction of the superficial incisions which must be made to secure the gluteal artery and the sciatic or pudic arteries.

A. Posterior superior iliac spine.

B. Great trochanter.

C. Tuberosity of the ischium.

D. Anterior superior iliac spine.

- A. B.—Ilio-trochanteric line, divided into thirds. This line corresponds in direction with the fibres of the gluteus maximus muscle. The incision to reach the gluteal artery is indicated by the darker portion of the line. Its centre is at the junction of the upper with the middle third of the ilio-trochanteric line and exactly corresponds with the point of emergence of the gluteal artery from the great sciatic notch.
- A. C.—Ilio-ischiatic line. The incision to reach the sciatic artery, or internal pudic, is indicated by the lower dark line. It is also to be made in the direction of the fibres of the gluteus maximus muscle. The centre of the wound corresponds to the junction of the lower with the middle third of the ilio-ischiatic line.

trochanter to the posterior superior spine, terminating about an inch and a half from the spine (Fig. 91). The superficial wound thus made will correspond in direction with the fibres of the gluteus maximus muscle. Divide the gluteus maximus the full length of the external wound. It may be necessary to divide a portion of the gluteus medius muscle as well. Separate the pyriformis and gluteus medius muscles, and search for the upper border of the great sciatic notch. Tie the artery as deeply as possible, almost within the pelvis, as it divides immediately after its emergence. The two veins by which it is accompanied should, if possible, be excluded from the ligature. John Bell narrates the particulars of an enormous traumatic aneurism, where he cut into the sac, turned out the clots, and ligatured the gluteal artery. This probably was the first case of the kind. ("Principles of Surgery," 1801.)

LIGATURE OF THE SCIATIC AND INTERNAL PUDIC ARTERIES.

Indication.—Wounds.

Surgical Anatomy.—The sciatic and internal pudic arteries and sciatic nerve emerge below the inferior border of the pyriformis muscle, escaping from the pelvis through the lower part of the great sacro-sciatic notch, accompanied by the greater and lesser sciatic nerves. The pudic artery is first posterior and then internal to the great sciatic nerve. It lies behind the root of the spinous process of the ischium and the external rotators of the hip. The pudic artery is at first somewhat external to the sciatic. Opposite the spine of the ischium it crosses in front of it to the inner side (Fig. 90).

Guide.—Rotate the limb inwards, and draw a line (Fig. 91, A C) from the posterior superior spine to the ischial tuberosity. The point of emergence of the internal pudic and sciatic arteries corresponds to the junction of the middle and lower thirds of this line.

Operation.—In the situation indicated, an incision should be made, about four inches in length, parallel to the fibres of the gluteus maximus, and after this muscle has been cut through, the artery must be sought for below the margin of the pyriformis. Feel for the spine of the ischium over which the pudic artery crosses and where it may be secured. The

sciatic artery will be found half an inch more external. Tie the vessels just above the lesser sacro-sciatic ligament, or at the seat of injury.

The sciatic as well as the internal pudic may be reached by a nearly vertical incision in the line drawn from the posterior superior spine to the ischial tuberosity which is indicated in the figure, about an inch and a half lower down than that made to reach the gluteal artery, but the incision made in the direction of the fibres of the gluteus maximus, as previously described, is preferable.

LIGATURE OF THE COMMON ILIAC ARTERY.

Indications.—Ligature may be required for gunshot and other wounds of the pelvic arteries, and for aneurism of the external or internal iliac arteries, also on account of hæmorrhage from these vessels, or from branches of the internal iliac. It has likewise been ligatured as a preliminary to the removal of vascular tumours. The common iliac was first tied by Gibson, in 1812, for gunshot wound of the artery. The peritoneal cavity was opened. Mott ligatured it in 1827 by the extra-peritoneal method. Out of fifty-five recorded cases in which the artery has been tied, fifty died, a mortality of 78·0 per cent. The great majority were men, and all the operations, save three or four, were performed before the introduction of antiseptic methods.

Anatomical relations.—The position and relations of this vessel are very constant. The length is variable, the average being one and a half to two inches. The artery passes obliquely downwards and outwards from its origin at the bifurcation of the aorta upon the lower part of the fourth lumbar vertebra, to divide into the external and internal iliacs opposite the junction of the last lumbar vertebra with the sacrum, where it is usually crossed by the ureter (Figs. 92, 93).

As a rule the vessel gives off only very small branches. The right common iliac is somewhat longer and larger than the left, and runs more obliquely outwards across the body of the fourth and fifth lumbar vertebræ, from which it is separated above by the two common iliac veins at their entrance into the vena cava. The right vein is the shorter and the left the longer. The artery is covered in front by branches of the sympathetic nerve, the

peritoneum, and the coils of the ileum. Near its origin it is in relation on its outer side with the vena cava, and right common iliac vein, and below with the psoas magnus muscle.

The left common iliac artery has the vein on the inner side, and partly behind it. The psoas is external. In front lie the rectum, superior hæmorrhoidal artery, branches of the sympathetic, and the ureter which crosses its termination.

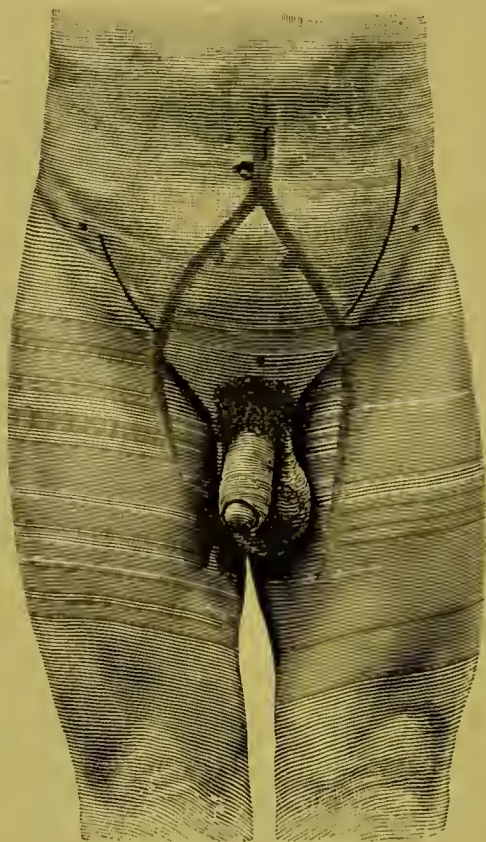

FIG. 92.—Direction of the common and external iliac arteries and the position of the superficial incisions adopted for their ligation. On the right side is that for the external iliac, and on the left side that for the common iliac artery.

Direction.—The aorta bifurcates on the lower part of the body of the fourth lumbar vertebra, a point corresponding in level with a horizontal line joining the highest portions of the iliac crests, or a little below the level of the umbilicus (Fig. 92). The position of the common iliac artery, therefore, nearly corresponds to the upper third of a line drawn from a

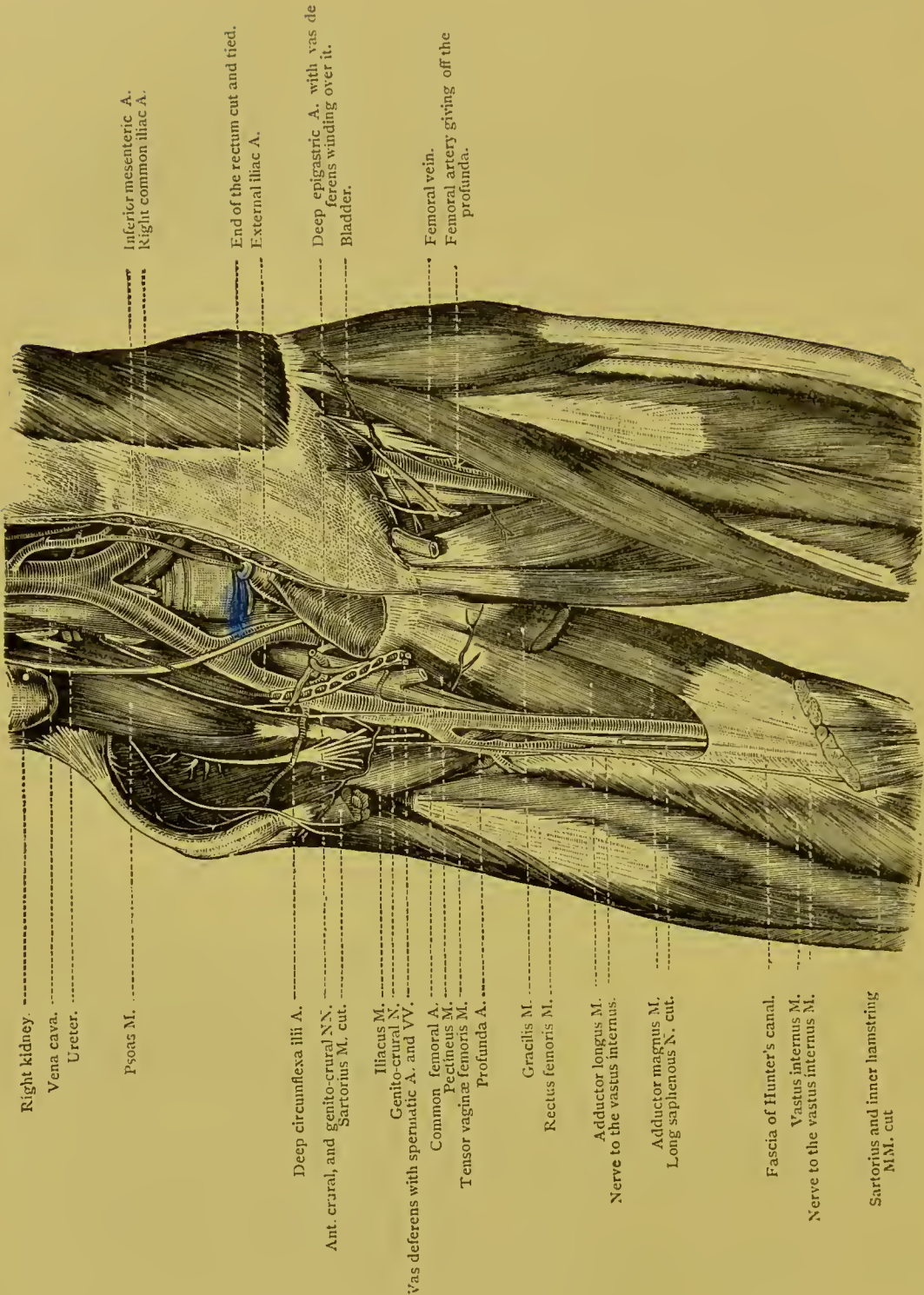
point three-quarters of an inch below and a little to the left of the umbilicus to the mid-point between the anterior superior spine of the ilium and the pubic symphysis.

Operation.—To Dr. Mott belongs the credit of having devised the present mode of operating. He was the first to apply a ligature to this vessel for aneurism. The operation proved perfectly successful. The operation is very difficult, from the great depth at which the vessel lies and the risk of injuring the peritoneum. The incision is similar to, but more external, and higher up than, that for the external iliac. Begin it one inch above and external to the middle of Poupart's ligament (Fig. 92), and prolong it two inches above and internal to the anterior superior spine. After careful division of the abdominal muscles and transversalis fascia, displace the peritoneum towards the median line as far as the inner border of the psoas, avoiding the genito-crural nerve. The ureter is usually lifted up with the peritoneum. Then seek the bifurcation on the sacro-iliac articulation. The artery will be exposed on further retracting the soft parts towards the middle line. Isolate the artery with the end of the director. Carefully avoid injuring the vein when passing the aneurism needle from within outwards on the left side, and on the right side from without inwards. This part of the operation is very difficult.

Another method is to make a curvilinear incision from the tip of the last rib to the anterior superior iliac spine, with its concavity directed forwards. The subsequent steps are the same.

Collateral Circulation (Fig. 89).

<i>Superior hæmorrhoidal of inferior mesenteric</i>	} with	{ <i>Middle and inferior hæmorrhoidal of internal iliac.</i>
<i>Middle sacral of aorta</i>		
<i>Internal mammary</i>	} with	<i>Deep epigastric.</i>
<i>Inferior intercostals</i>		
<i>Lumbar arteries</i>		
<i>Internal mammary and long thoracic</i>	with	<i>Superficial epigastric.</i>
<i>Last lumbar of aorta</i>	with	{ <i>Lumbar branch of ilio-lumbar, and with circumflex iliac.</i>
<i>Posterior branches of middle sacral, and of lateral sacral of opposite side</i>	} with	<i>Superficial branches of gluteal.</i>



Right kidney.

Vena cava.

Ureter.

Psoas M.

Inferior mesenteric A.
Right common iliac A.

End of the rectum cut and tied.
External iliac A.

Deep circumflexa ili A.

Ant. crural, and genito-crural NN.
Sartorius M. cut.

Iliacus M.
Genito-crural N.
Common femoral A.

Pectineus M.
Tensor vaginae femoris M.
Profunda A.

Deep epigastric A. with vas de
ferens winding over it.
Bladder.

Femoral vein.
Femoral artery giving off the
profunda.

Gracilis M.

Rectus femoris M.

Adductor longus M.
Nerve to the vastus internus.

Adductor magnus M.
Long saphenous N. cut.

Fascia of Hunter's canal.

Vastus internus M.
Nerve to the vastus internus M.

Sartorius and inner hamstring
MM. cut

FIG. 93.—Surgical anatomy of the aorta, iliac and femoral arteries.

<i>Spermatic artery from aorta</i>	with	{	<i>Artery of vas deferens (superior vesical).</i>
			<i>Cremasteric of deep epigastric.</i>
<i>Pudic branch of obturator</i>	with	{	<i>Fellow of opposite side, and pudic branch of deep epigastric.</i>

In addition, many small anastomoses occur in the middle line, between corresponding branches of the opposite internal iliacs.

LIGATURE OF THE ABDOMINAL AORTA.

Indications.—The abdominal aorta has been ligatured nine times, usually for aneurism of the iliac arteries, close to the bifurcation, and below the origin of the inferior mesenteric artery. All the cases terminated fatally.

Anatomical relations.—That portion of the vessel—about two inches in length—between the giving off of the inferior mesenteric and the bifurcation is the most accessible. The aorta bifurcates on the lower part of the body of the fourth lumbar vertebra, a point nearly corresponding to the umbilicus, either in the median line, or to one or other side, more frequently to the left. The portion of the artery below the origin of the inferior mesenteric (Fig. 93) is covered by the small intestines, mesentery, and branches of the aortic plexus of the sympathetic. It is separated from the vertebræ by the left lumbar veins. The vena cava lies to the right side and slightly behind it.

Operation.—The artery was first ligated by Sir Astley Cooper, in 1817, for an aneurism of the left external iliac. The patient died apparently of peritonitis. Antiseptic precautions will in future exclude or very greatly diminish this risk. The vessel may be exposed, according to Cooper's plan, by an incision about four inches long through the abdominal wall in the median line. Its centre should correspond to the umbilicus. The incision must skirt the left side of the umbilicus to avoid injuring the round ligament of the liver, and the remains of the urachus. The intestines having been pushed aside, the posterior peritoneal layer is to be divided, and the artery exposed. Pass the aneurism needle from the right to the left side.

Another method is that by left lumbar incision. In this the peritoneal cavity is unopened; but the extreme depth of the wound renders the necessary manipulations very difficult. The incision extends from the extremity of the tenth rib downwards for five or six inches to a point an inch internal to the anterior superior spine of the ilium. The abdominal muscles having been cut through *seriatim*, the transversalis fascia is exposed and carefully divided, the peritoneum is then gently detached and raised up in the direction of the middle line until the vessels are found. The first to be exposed will be the common iliac artery, and this is to be traced upwards till the aorta shall be reached. The wound so formed is very deep, but it has the advantage of not opening the peritoneal cavity. Care should be taken not to include the aortic plexus in the ligature. In animals when this plexus has been included in the noose, the lower extremities are paralyzed, and death speedily follows. The operation has never been successful, and the occurrence of circumstances justifying recourse to it must be exceedingly rare.

Collateral Circulation.

CARDIAC SIDE.		DISTAL SIDE.
<i>Internal mammary (superior epigastric branch)</i>	} with	{ <i>Deep epigastric of external iliac.</i> <i>Superficial epigastric of femoral.</i>
<i>Inferior mesenteric by superior hæmorrhoidal branch</i>	} with	{ <i>Internal iliac (middle hæmorrhoidal).</i>
<i>Lower intercostal arteries</i> <i>Lumbar arteries (above ligature)</i>	} with	{ <i>Branches of deep epigastric.</i> <i>Lumbar arteries below ligature.</i> <i>Lumbar branch of ilio-lumbar.</i> <i>Branches of circumflex iliac.</i>

I N D E X.

A

Anatomy—

Abd. aorta, 133
 Ant. tibial, 102
 Axillary, 53
 Brachial, 47, 49, 51, 52
 Com. carotid, 79
 Com. femoral, 119
 Com. iliac, 129
 Dorsalis pedis, 99
 Ext. carotid, 83
 Ext. iliac, 122
 Facial, 91
 Gluteal, 125
 Innominate, 73
 Inf. thyroid, 69
 Int. carotid, 87
 Int. iliac, 124
 Int. mammary, 72
 Int. pudic, 128
 Lingual, 89
 Middle meningeal, 95
 Occipital, 93
 Palmar arch, supfl. 40
 Palmar arch, deep, 41
 Peroneal, 108
 Plantar arteries, 98
 Popliteal, 109
 Post. auricular, 91
 Post. tibial, 106
 Radial, 42, 43, 44, 45
 Sciatic, 128

Anatomy—(continued.)

Subclavian, 58, 61, 64, 65
 Sup. thyroid, 88
 Supfl. femoral, 112, 113
 Temporal, 94
 Ulnar, 45
 Vertebral, 66
 Anel's method of ligature, 3
 Treatment of varicose aneurism at
 bend of elbow, 47
 Aneurism—
 Recurrent pulsation, 35
 Sac, changes in, subsequent to ligature,
 30
 Suppuration of sac, 36
 Antyllus' mode of treating aneurism, 15
 Cases suited for, 6, 35
 Syme's advocacy of, 6
 Archigenes, lig. of main artery prior to
 operation, 9

B

Barwell, distal lig. of carotid, 76
 Bell, Sir C., treatment of gluteal aneurism,
 125, 128
 Bell, J., treatment of gluteal aneurism, 6,
 125, 128
 Birch, lig. of femoral for popliteal aneurism,
 111
 Blizard, Sir T., lig. of sup. thyroid artery
 for goitre, 9

Brasdor's method of ligature, 4
 Indications for, 9, 76

C

Carcinoma of tongue, lig. of lingual for, 9
 Carnochan, lig. of femoral for elephantiasis,
 III
 Catgut ligature, 21, 29
 Cervical rib supernumerary pushing forward
 subclavian artery, 58
 Chassaignac, tubercle of, 82
 Cock, lig. of mid. meningeal, 97
 Collateral circulation after lig. of—
 Abd. aorta, 134
 Ant. tibial, 104
 Axillary, 57
 Brachial, 34, 52
 Common carotid, 83
 Common iliac, 131
 Com. femoral, 33, 121
 External iliac, 123
 Innominate, 75
 Internal iliac, 124
 Post. tibial, 107, 108
 Subclavian, 65
 Suppl. femoral, 33, 115, 121
 Vertebral, 66
 Collateral circulation, 31
 Points affecting establishment of, 32
 Comminuted fracture, lig. of main artery
 in, 7
 Cooper, Sir A., lig. of abd. aorta, 133

D

Desault, distal ligature of carotid, 76
 Deschamps' distal ligature, 5, 7, 6
 Distal ligature, 4
 Drainage, 23
 Drainage tubes, introduction of, 23
 Dupuytren, lig. of subclavian in second
 stage, 65

E

Elephantiasis, lig. of femoral for, 9, III
 Epilepsy, ligature of vertebral for, 9, 66
 Lig. of carotid for, 77

Erichsen, lig. of mid. meningeal, 97
 Esmarch's bandage, effect of, on aneurismal
 sac, 31

G

Gangrene after ligature, 36
 Gibson, lig. of common iliac, 129
 Goitre, lig. of sup. thyroid for, 9
 Graefe, lig. of carotid prior to removal of
 jaw, 9
 Guthrie, incision for lig. of axillary in first
 part, 57

H

Heath, C., distal lig. of carotid, 76
 Hebenstreit, distal lig. of carotid, 76
 Hewett, Sir P., lig. of mid. meningeal, 97
 Home, Sir E., theory of cure of aneurism,
 4
 Hueter, lig. of mid. meningeal, 97
 Hunter, lig. of femoral for popliteal aneur-
 ism, III
 Hunterian lig., 3
 Indications for, 8, 9

J

Jones, temporary deligation, 29

L

Lange, lig. of sup. thyroid artery, for
 goitre, 9
 Ligature—
 Action of, upon vessel, 23
 After-treatment, 32
 Application of loop, 18
 Causes of failure after, 35
 Complications and causes of death
 after, 35
 Contra-indications to, 9
 Double ligature, theory of, 21
 Formation of temporary clot, 24
 Permanent, 25
 Gangrene after 36
 Indications for, 6

Ligature—(*continued.*)

- Instruments needed, 10
 - Material, 20, 21, 29
 - Mode of exposing vessel, 12
 - Mode of operation, 10
 - Position of patient, 10
 - Sec. hæmorrhage, 36
 - Separation of, 37
 - Temporary, 29
 - Varieties of knot (reef knot, double hitch, granny), 20
- Ligature of arteries—
- Abd. aorta, 133
 - Ant. tibial, 100
 - Lower third, 103
 - Middle third, 104
 - Upper third, 104
 - Axillary, 53
 - In third stage, 55
 - In second stage, 56
 - In first stage, 56
 - Brachial, 47
 - At bend of elbow, 49
 - In lower two-thirds, 51
 - In upper third, 52
 - Common carotid, 76
 - Above omo-hyoid, 81
 - Below omo-hyoid, 81
 - Com. iliac, 129
 - Com. femoral, 119
 - Digital arteries, 38
 - Dorsalis pedis, 99
 - Ext. carotid, 83
 - Ext. iliac, 121
 - Facial, 91
 - Gluteal, 125
 - Inf. thyroid, 69
 - Innominate, 73
 - Int. carotid, 87
 - Int. iliac, 124
 - Int. mammary, 72
 - Int. pudic, 128
 - Lingual, 88
 - Mid. meningeal, ant. branch, 95
 - Occipital, 93
 - Palmar arches, 38
 - Deep, 41

Ligature of arteries—(*continued.*)

- Palmar arches, superficial, 40
 - Peroneal, 108
 - Plantar arteries, 98
 - Popliteal, 109
 - Post. auricular, 91
 - Post. tibial, 105
 - Lower third, 106
 - Middle third, 106
 - Upper third, 108
 - Radial, 42
 - In Tabatière anatomique, 43
 - In lower third, 44
 - Middle third, 45
 - Upper third, 45
 - Sciatic, 128
 - Subclavian—
 - In first stage, 65
 - In second stage, 64
 - In third stage, 61
 - Sup. thyroid, 88
 - Supfl. femoral, 111
 - In Hunter's canal, 113
 - At apex of Scarpa's triangle, 113
 - Temporal, 94
 - Ulnar artery, 45
 - In lower third, 46
 - In middle third, 46
 - In upper third, 47
 - Vertebral, 66
- Little, lig. of femoral or acute inflam. of knee-joint, 111

M

- Maunder, lig. of femoral for acute inflam. of knee-joint, 111
- Mott, lig. of carotid prior to removal of jaw, 9
 - Lig of common iliac, 129, 131
 - Lig. of innominate, 73

P

- Physick, Prof., use of animal ligatures, 29
- Presse-artère, 30
- Pupil, contraction of, after lig. of vertebral, 69

R

Ramsden, lig. of subclavian in third part, 59
 Recurrent pulsation after ligature of artery, 35

S

Scarpa, necessity of division of middle and int. coats, 28
 Secondary hæmorrhage, 36
 Silk ligature, 20, 29
 Smyth, lig. of innominate, 73
 Lig. of vertebral, 66
 Socin, lig. of mid. meningeal, 97
 Stevens, lig. of int. iliac, 124

Suppuration of sac, 36
 Syme, treatment of gluteal aneurism, 125

T

Thompson, lig. of innominate, 73
 Thrombus, 24
 Organization of 26
 Permanent, 25
 Temporary, 24
 Travers, temporary deligation, 29

W

Wardrop, method of ligature, 5
 Indications for, 9, 76

END OF PART I.



